



*This guide was developed to assist GPs in investigating symptoms that could be breast cancer. The individual patient history and circumstances (eg, a very strong family history or previous personal history of breast cancer) must be taken into account and may influence the investigative process for any particular woman. This is a guide to appropriate practice subject to the medical practitioner's judgment of each individual case. Cancer Australia does not accept any liability for any injury, loss or damage incurred by use of or reliance on the information.*

# The investigation of a new breast symptom

## a guide for General Practitioners

FEBRUARY 2006



Endorsed by



ROYAL AUSTRALASIAN  
COLLEGE OF SURGEONS



### INTRODUCTION

This guide has been developed to maximise the effectiveness of investigation of women who present to their general practitioner with a new breast symptom.

A review of the evidence forms the basis of the recommendations. Where the evidence is lacking, expert consensus opinion has been incorporated.

It is acknowledged that expertise and resource availability may vary across different practice settings.

### THE TRIPLE TEST APPROACH TO DIAGNOSIS

The triple test refers to three diagnostic components:

- medical history and clinical breast examination
- imaging – mammography and/or ultrasound
- non-excision biopsy – fine needle aspiration (FNA) cytology and/or core biopsy.

The sensitivity of the 'triple test' is greater than any of the individual components alone. **The triple test is positive if any component is indeterminate, suspicious or malignant.**

The correct sequencing of tests is important to the overall interpretation of the results (refer to flow chart).

It is the responsibility of the managing clinician to correlate the cytological/histological results with the clinical and imaging findings.

### Relative frequencies of presenting symptoms of breast cancer\*

Lump	76%
Pain alone	10%
Nipple changes	8%
Breast asymmetry or skin dimpling	4%
Nipple discharge	2%

\* Based on the presentation of symptomatic women to the Breast Unit of the Peter MacCallum Cancer Centre, Melbourne, in 2004. We acknowledge the assistance of the Unit and Henderson MA, Power AM and McPhail T for providing the information.

### PATIENT HISTORY AND CLINICAL EXAMINATION

A detailed history and thorough clinical examination provide important information on which to base further investigation, and should be accurately documented.

#### Patient history

Relevant history includes details of:

- current medications or recent changes in medication, especially exogenous hormones
- hormonal status / menstrual history
- parity / age at first full-term pregnancy
- previous breast problems, particularly previous breast investigations, biopsy results
- risk factors, particularly strong family history of breast / ovarian cancer. For further information see [Advice about familial aspects of breast cancer and ovarian cancer: a guide for health professionals](#)
- most recent imaging / date and results / screening or diagnostic.

#### History of presenting symptom

- site — constant or changing
- duration — when and how first noted
- any changes since first noted
- relationship to menstrual cycles or exogenous hormones
- associated symptoms.

### NIPPLE CHANGES

Benign nipple changes include:

- slit-like retraction
- able to be everted.

Clinically abnormal or suspicious nipple changes:

- colour change
- fixed whole nipple inversion
- ulceration.

### Clinical breast examination

**Inspection** should take place in a good light and with the patient:

1. with arms by her side
2. with arms raised above head
3. pressing on hips and leaning forward (contracting pectoral muscles).

Pay particular attention to:

- breast contours — skin changes such as erythema, dimpling or puckering, peau d'orange, visible lumps
- nipples — height, any inversion, erythema, eczema, nodules, ulcers.

The ability to identify breast cancers by palpation is influenced by the characteristics of the tumour, the surrounding breast tissue and the position of the lesion in the breast.

**Palpation** with the flat of the fingers:

patient seated or standing:

- palpate supraclavicular and axillary fossae
- palpate breasts, particularly upper quadrants and bimanual examination

patient lying flat with ipsilateral arm behind her head:

- palpate all quadrants and axillary tail and around and behind nipple
- the non-examining hand may be used to immobilise a large breast
- a pillow positioned under the shoulder may assist in examining the outer quadrants of a large breast.

#### Recording

Details of any lump — including size, shape, consistency, mobility, tenderness, fixation and exact position - should be recorded.

## THE TRIPLE TEST

The table below is presented to help clinicians interpret the probability of cancer based on diagnostic information from the triple test and its components.

### Accuracy of the triple test and each of its components

	Triple Test	Clinical Examination	Imaging (Mammography & Ultrasound)	Non-excision Biopsy (FNAC & Core Biopsy)
TPR, %	> 99.6	85	95	90
FPR, %	< 38	20	8	0.5
Specificity, %	> 62	90	92	99.5

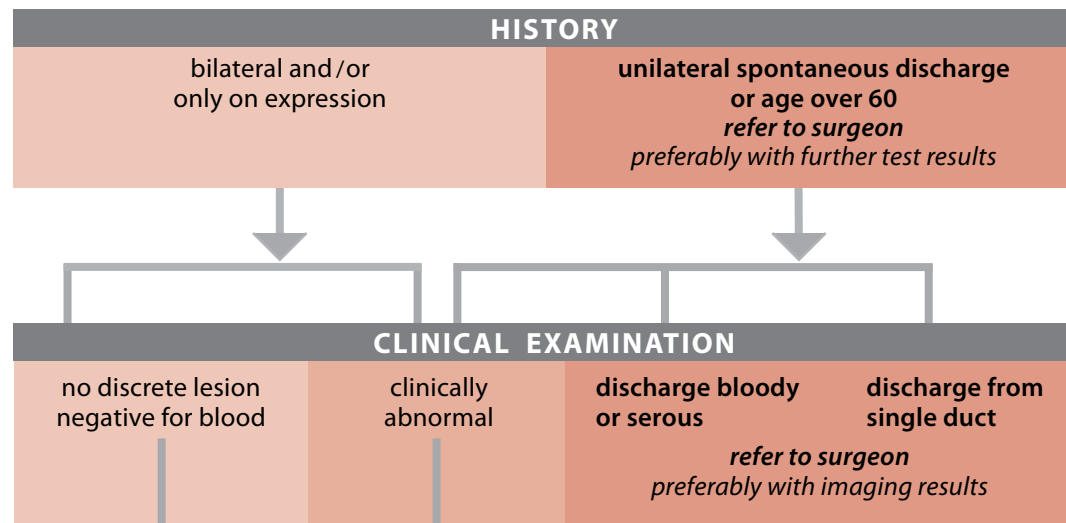
TPR = True Positive Rate (sensitivity) FPR = False Positive Rate (1 - specificity)

### Implications for practice

The triple test is the recommended approach to maximise diagnostic accuracy in the investigation of breast changes.

- A **triple test positive (indeterminate, suspicious or malignant)** was found in 99.6% of breast cancers. Any positive result requires specialist referral and further investigation, with the likelihood of cancer increasing if more than one component is positive.
- A **triple test negative** on all components provides good evidence that cancer is unlikely (less than 1%) and further investigation can be avoided for most of these women (if there are no other high risk factors).
- Where **symptoms persist** or there are **high risk factors** such as strong family history or previous personal history of breast cancer, or the woman remains concerned, a specialist opinion may be warranted.

## The investigation of a new nipple discharge



- advise to cease expression
- mammogram if due (follow screening guidelines)
- review in 2–3 months
- **if persistent bilateral discharge, do serum prolactin levels and consider referral**

- follow diagnostic procedure as for 'Investigation of a new breast symptom'

## NIPPLE DISCHARGE

### Probability (%) of cancer by age and nature of discharge

	Age <60	Age >60
Serous	<1	3
Bloody	3	9

In women with nipple discharge, most cancers occur in women who have a bloody or serous discharge or are 60 years or older, necessitating further investigation. Discharge cytology has low sensitivity (45%) but is highly specific for cancer.

### Implications for practice

- Spontaneous, unilateral, bloody or serous discharge from a single duct raises the possibility of cancer, especially if it occurs in older women.
- Positive discharge cytology result is indicative of cancer, but a negative result cannot be used to rule out the disease.
- The use of galactography should be based on the availability of expertise, preferably after consultation with a surgeon.

# The investigation of a new breast symptom (other than nipple discharge)

## HISTORY

## CLINICAL EXAMINATION

no lump  
no discrete lesion

thickening or nodularity  
consistent with  
hormonal change

clinically benign mass or  
benign nipple change

don't know

**suspicious or malignant**  
breast or nipple change

*refer to surgeon, preferably with further test results*

- mammogram if due (follow screening guidelines)
- treat any pain
- review in 2—3 months (immediately after period) and
- if problem persists, send for imaging (see below)

## IMAGING: MAMMOGRAPHY AND/OR ULTRASOUND (SEE NOTES)

normal breast tissue or no discrete lesion (category 1)\*

benign (category 2)\*

**indeterminate / equivocal**  
(category 3)\*

**suspicious or malignant**  
(category 4 or 5)\*

simple cyst

*if symptomatic*

solid lesion or complex cyst

*refer to surgeon  
irrespective of other test results*

- if consistent with clinical findings:
  - reassure
  - advise re breast awareness
  - advise re future screening
- if inconsistent with clinical findings non excisional biopsy required

## FINE NEEDLE ASPIRATION

normal fluid  
(straw to dark green),  
and no lump remains

bloody fluid  
(not traumatic)  
and no lump remains

**lump remains**  
(whether normal  
or bloody fluid)

- reassure
- advise review if refills
- if persistent refilling **refer to surgeon**

send fluid to cytology

*refer to surgeon  
irrespective of pathology*

further views  
may be helpful

## PATHOLOGY: FNA CYTOLOGY OR CORE BIOPSY (SEE NOTES)

inadequate / insufficient  
(category 1)\*\*

adequate and representative specimen

benign  
(category 2)\*\*

**atypical / indeterminate**  
(category 3)\*\*

**suspicious or malignant**  
(category 4 or 5)\*\*

if all previous results  
benign, repeat biopsy  
**otherwise  
refer to surgeon**

if consistent with clinical and  
imaging findings, reassure  
**if inconsistent  
refer to surgeon**

**refer to surgeon**

\* Standardised breast imaging classification system – see [Breast imaging: a guide for practice](#)

\*\* Standardised FNA cytology and core biopsy classification system – see [Breast fine needle aspiration cytology and core biopsy: a guide for practice](#)

## DIAGNOSTIC IMAGING

The sensitivity of mammography increases with increasing age. Sensitivity is improved with the addition of ultrasound over all ages though the size of this benefit is greater in women under the age of 50 years. Ultrasound is more sensitive than mammography in the detection of cancer in younger women. Given the limitations of both mammography and ultrasound, they are often used in a complementary capacity to give information in the evaluation of breast abnormalities. Referring doctors may consult with their radiologist about the most appropriate test for individual cases.

### Implications for practice

Providing a detailed history will assist the radiologist to perform appropriate targeted imaging. **Mammography should be performed in all age groups if the clinical or ultrasound findings are suspicious or malignant.**

#### Under age 25

- **Ultrasound** is recommended as the first imaging modality.
- **Mammography** is only recommended if the clinical or ultrasound findings are suspicious or malignant.

#### 25-34 years

- **Ultrasound** is recommended as the first imaging modality.
- **Mammography** should be used in addition to ultrasound if:
  - the clinical findings are suspicious or malignant or
  - the ultrasound findings are indeterminate, suspicious or malignant (imaging classification category 3, 4 or 5) or
  - the ultrasound findings are not consistent with clinical findings.
- **Mammography** may be used in addition to ultrasound if:
  - there is a strong family history of breast cancer.

#### 35-50 years

- In keeping with expert consensus opinion **mammography and targetted ultrasound** are used as complementary modalities for the evaluation of symptomatic women in this age group
- In the absence of strong evidence comparing these modalities, no absolute age recommendation can be provided in relation to the use of **mammography or ultrasound** as the initial imaging modality for symptomatic women in the age range 35 – 50 years.

#### Over 50 years

- **Mammography** is recommended as the first imaging modality.
- **Ultrasound** is an acceptable initial investigation if:
  - the lump is clinically consistent with a simple cyst and a normal (non-cancerous) mammogram has been performed in the last year. If the ultrasound does not confirm a typical cyst, further investigation including mammography must be performed.
- **Ultrasound** should be used in addition to mammography:
  - if there is a clinical abnormality and either the mammogram is normal or the mammogram is unhelpful, eg extensive dense parenchyma or
  - if the mammogram is inconsistent with the clinical finding.
- **Ultrasound** may be used in addition to mammography:
  - to guide a fine needle aspiration or core biopsy or
  - to help characterise mammographic abnormalities.

#### In pregnancy or lactation

- **Ultrasound** is the most useful modality
- **Mammography** should be used if the clinical or ultrasound findings are indeterminate, suspicious or malignant or there is inconsistency between test results.

## NON-EXCISIONAL BIOPSY

Both fine needle aspiration (FNA) cytology and core biopsy have been shown to have high specificity and sensitivity when used for palpable and impalpable lesions.

### Implications for practice

- There are no absolute rules determining when FNA cytology or core biopsy is the more appropriate investigation.
- FNA cytology and core biopsy are complementary, although one may be more appropriate in achieving a definitive diagnosis. Core biopsy can often demonstrate invasive disease whereas FNA cannot differentiate between in situ and invasive cancer. Core biopsy can be used when FNA cytology fails to correlate with clinical findings or imaging studies. For further information see [Fine needle aspiration cytology and core biopsy: a guide for practice](#).

## SURGICAL REFERRAL

Where surgical referral is recommended, this referral should preferably be to a surgeon with expertise in breast disease. Members of the RACS breast section: [www.surgeons.org](http://www.surgeons.org)

### Implications for practice

Surgical referral is recommended, in any of the following situations:

- where any one component of the triple test is positive i.e:
  - clinical examination (suspicious or malignant)
  - imaging (indeterminate, suspicious or malignant – classification category 3, 4 or 5)
  - FNA cytology or core biopsy (indeterminate, suspicious or malignant – classification category 3, 4 or 5)
- where a cyst aspiration is incomplete, results in bloody aspirate (not traumatic) or lump remains post-aspiration
- spontaneous unilateral discharge from a single duct especially in women 60 years and over
- if any test result is inconsistent and requires additional investigation.

## FURTHER INFORMATION

Relevant resources for the investigation of a new breast symptom include:

### For clinicians:

[Advice about familial aspects of breast cancer and epithelial ovarian cancer: a guide for health professionals](#) (card)

[Breast imaging: a guide for practice](#) (booklet)

[Fine needle aspiration cytology and core biopsy: a guide for practice](#) (booklet)

[Clinical practice guidelines for the management of the women with early breast cancer](#) (booklet)

### For women: (including translated versions)

[Information for women about family history of breast cancer and ovarian cancer](#) (factsheet)

[Guide for women with early breast cancer](#) (booklet)

To access these guides and other information on breast cancer visit:  
[www.canceraustralia.gov.au](http://www.canceraustralia.gov.au)