



**Australian Government**

**Cancer Australia**

## **IMPORTANT NOTICE**

# **Rescinded**

This resource is 10 years or older and has been rescinded by Cancer Australia. It is available to the public for research and reference purposes only. Cancer Australia assumes no legal liability or responsibility for errors or omissions contained within.

This resource was rescinded on 16 December 2014.



Symbol of quality information about women's cancers



**NATIONAL BREAST  
CANCER CENTRE**

Incorporating the  
Ovarian Cancer Program

# Breast imaging: a guide for practice

Breast imaging: a guide for practice

# Breast imaging: a guide for practice

Endorsed by



---

The Royal  
Australian and  
New Zealand  
College of  
Radiologists

---

© National Breast Cancer Centre 2002  
ISBN Print: 1 876319 74 7 Online: 1 876319 75 5

This work is copyright. Apart from any use permitted under the *Copyright Act 1968*, no part may be reproduced by any process without prior written permission from National Breast Cancer Centre. Requests and enquiries concerning reproduction and rights should be addressed to the Copyright Office, National Breast Cancer Centre, Locked Bag 16, Camperdown NSW 1450.  
Website: [www.nbcc.org.au](http://www.nbcc.org.au) Email: [director@nbcc.org.au](mailto:director@nbcc.org.au)

# CONTENTS

<b>Foreword</b>	<b>4</b>
<b>Abbreviations</b>	<b>5</b>
<b>Introduction and background</b>	<b>6</b>
<b>Summary</b>	<b>10</b>
<b>Chapter 1 An introduction to breast imaging</b>	<b>14</b>
Background	14
General principles of breast imaging	15
Use of mammography	16
Use of ultrasound	17
Combined use of mammography and ultrasound	19
Summary points	20
<b>Chapter 2 The context for breast imaging</b>	<b>21</b>
The triple test approach to diagnosis	22
Clinical perspectives of what is required from breast imaging	22
Summary points	29
<b>Chapter 3 Requesting breast imaging</b>	<b>30</b>
Summary point	32
<b>Chapter 4 Preparing women for breast imaging</b>	<b>33</b>
Effective communication	33
Providing information	34
Summary points	36

<b>Chapter 5 Tailoring the breast imaging examination</b>	<b>37</b>
Imaging the asymptomatic woman	37
Imaging the symptomatic woman	37
Imaging the pregnant/lactating woman with a mass	42
Imaging the woman following treatment for breast cancer	42
Imaging the woman with breast implants	44
Evaluation of incidental findings detected by imaging	45
Addressing the woman's needs during breast imaging	46
Summary points	48
<b>Chapter 6 Reporting breast imaging</b>	<b>49</b>
Standardised reporting	49
Level of significance of radiological findings – a classification system	50
Clinical perspectives of a good imaging report	52
Summary point	55
<b>Chapter 7 Communicating results to the woman</b>	<b>56</b>
Summary point	58
<b>Chapter 8 Quality improvement</b>	<b>59</b>
External audit	59
Internal audit	59
Summary point	61
<b>Chapter 9 Training and continuing education</b>	<b>62</b>
Opportunities within Australia	63
International opportunities	65
Summary point	65

<b>Chapter 10 Other imaging modalities</b>	<b>66</b>
Commercially available imaging modalities	66
Emerging technologies	68
Summary points	68
<b>Appendix A Project team members</b>	<b>69</b>
<b>Appendix B Diagnostic imaging options</b>	<b>70</b>
<b>Appendix C Example of a request form for breast imaging</b>	<b>71</b>
<b>Appendix D A tool for assessing whether a woman is at increased risk of developing breast cancer due to family history</b>	<b>73</b>
<b>Appendix E Summary of useful strategies to prepare women for breast imaging</b>	<b>77</b>
<b>Appendix F Labelling of imaging films</b>	<b>80</b>
<b>Appendix G A standardised report for breast imaging</b>	<b>81</b>
Breast imaging summary	84
<b>Appendix H Contacts for training and continuing education</b>	<b>86</b>
<b>Glossary</b>	<b>89</b>
<b>References</b>	<b>94</b>

## FOREWORD

Breast imaging – principally via the modalities of mammography and breast ultrasound – is an important tool in the investigation of breast changes. Until now, no national recommendations have existed for breast imaging that occurs outside of the national mammographic screening program known as BreastScreen Australia.

*Breast imaging: a guide for practice* (‘the guide’) has been developed by a multidisciplinary project team, coordinated by the National Breast Cancer Centre (‘the Centre’). The guide’s focus is on breast imaging that occurs outside of the BreastScreen Australia Program.

While this guide is intended to improve the effectiveness and efficiency of the processes of referral to breast imaging services and the reporting of imaging results, it is not intended as a training manual. Given that the available literature does not meet the rigour required to develop clinical practice guidelines as outlined by the National Health and Medical Research Council (NHMRC),<sup>1</sup> *Breast imaging: a guide for practice* simply provides a series of recommendations and suggestions for practice.

The guide is particularly relevant for clinicians who refer women to breast imaging services and for clinicians reporting on the results. It is therefore primarily targeted at general practitioners, radiologists, surgeons, breast physicians, pathologists and oncologists. In addition, the guide also contains information relevant to those solely involved in producing the breast images, such as radiographers and sonographers. *Breast imaging: a guide for practice* may also be useful to nurses, supportive care professionals and other members of the multidisciplinary team.

We hope that the recommendations in this guide will help Australian clinicians to increase the effectiveness and efficiency of breast imaging in Australia and thus enhance women’s satisfaction with the process.



## **ABBREVIATIONS**

<b>AH</b>	atypical ductal hyperplasia <i>or</i> atypical lobular hyperplasia
<b>AIR</b>	Australian Institute of Radiography
<b>BIRADS</b>	Breast Imaging Reporting and Data System
<b>BIRG</b>	Breast Imaging Reference Group
<b>CC</b>	cranio-caudal
<b>the Centre</b>	National Breast Cancer Centre
<b>DCIS</b>	ductal carcinoma in situ
<b>FNA</b>	fine needle aspiration
<b>the guide</b>	<i>Breast imaging: a guide for practice</i>
<b>LCIS</b>	lobular carcinoma in situ
<b>MLO</b>	medio-lateral oblique
<b>MRI</b>	magnetic resonance imaging
<b>NHMRC</b>	National Health and Medical Research Council
<b>PET</b>	positron emission tomography
<b>RANZCR</b>	Royal Australian and New Zealand College of Radiologists

## INTRODUCTION AND BACKGROUND TO THE GUIDE

### Aim and scope

The overall aim of *Breast imaging: a guide for practice* is to optimise the early and accurate diagnosis of breast abnormalities. A secondary aim is to maximise both the woman's and the clinician's satisfaction with the breast imaging experience.

This guide is not intended to be prescriptive or to serve as a training manual, but rather to offer a guide to practice. While acknowledging that access to imaging services may be limited in some regions, the recommendations for practice are applicable to both rural/remote and urban practices across Australia. For instance, the common breast imaging modalities of mammography and ultrasound are widely available throughout Australia, although women in remote communities may still have to travel long distances for these.

*Breast imaging: a guide for practice* has been developed for imaging that occurs outside of the BreastScreen Australia Program. Its development is supported by the Royal Australian and New Zealand College of Radiologists (RANZCR), which identified the need for broader national recommendations that examine breast imaging conducted outside of the BreastScreen Australia Program.

This guide is intended to complement existing documents developed to improve the quality of breast imaging. For example, BreastScreen Australia's *National Accreditation Standards* outline standards for breast imaging in the national mammographic screening program.<sup>2</sup> The RANZCR has established both Mammography Standards<sup>3</sup> and medical imaging accreditation programs.<sup>4,5</sup> In addition, the RANZCR provides various policy statements on diagnostic ultrasound services, mammography and screening for women who carry BRCA1 mutations,<sup>6</sup> on the imaging of women with prostheses,<sup>7</sup> and on teleradiology.<sup>8</sup>

It is anticipated that this guide will also complement existing evidence-based documents for the investigation of women with breast symptoms<sup>9,25</sup> and the management of women with early breast cancer.<sup>41</sup>

As less than 0.9% of breast cancers occur in men<sup>10</sup> and breast imaging is mostly performed on women, the term ‘woman’ and feminine pronouns are used throughout the guide. However, the information and principles outlined in the guide are also applicable to men with breast abnormalities.<sup>11</sup>

## **Development**

A review by the Centre of relevant international breast imaging guidelines and performance standards<sup>12–16</sup> determined that the development of a new document was warranted, as existing documents required significant modification in order to be applicable to the Australian setting. *Breast imaging: a guide for practice* has been developed by a multidisciplinary project team coordinated by the Centre. The project team included representatives from the relevant professional colleges and BreastScreen Australia, clinicians from the primary audience and a consumer (See Appendix A). The development of this guide was overseen by the Centre’s Early Detection and Diagnosis Expert Advisory Group.

The project team adopted a consensus approach for considering the relevant evidence and formulating recommendations for practice.

Due to the paucity of relevant research data on several topics, some sections of this guide are essentially descriptive and many of its recommendations are based on the consensus opinion of the project team. Where evidence exists, the project team reviewed and considered the relevant literature and incorporated it as appropriate. As the level of evidence hierarchy advocated by the NHMRC does not readily apply to studies of diagnosis, it was considered inappropriate to allocate levels of evidence.

Each chapter in the guide provides comprehensive coverage of a relevant topic and a case-study approach is used to illustrate some key points. A summary of key points is provided at the end of each chapter.

## **Implications**

The investigation of a breast abnormality has psychosocial, economic and medico-legal implications for women and clinicians. The assessment of a breast change can be an anxiety-inducing experience for women, with well documented, adverse psychological consequences.<sup>17–22</sup>

An intended outcome of this guide is to improve appropriate referral to, and reporting of, breast imaging. While we do not know the exact impact such improvements may have on the health care system, it may reduce the number and cost of unnecessary investigations. There may also be a positive impact on the psychosocial wellbeing of individual women: a radiological practice that provides results in an accurate and timely manner will also enhance patient and clinician satisfaction.

## **Consultation process**

In September 2001, a draft of *Breast imaging: a guide for practice* was circulated for review to the following professional Australian colleges and organisations:

- RANZCR
- The Royal College of Pathologists of Australasia
- Royal Australasian College of Surgeons
- The Royal Australian College of General Practitioners
- Australasian Society of Breast Physicians
- Medical Oncology Group Australia
- Faculty of Radiation Oncology, RANZCR
- Australian Institute of Radiography
- Breast Cancer Network of Australia
- Australian Cancer Network
- BreastScreen Australia.

The guide was also reviewed by two international experts in the fields of radiology and surgery: Professor Peter Dempsey, radiologist, MD Anderson Cancer Centre, Houston, United States of America; and Mr James Bristol, surgeon and Director of the Breast Unit, Cheltenham District Hospital, United Kingdom.

The reviewers' comments were considered by the project team and the document was revised as appropriate.

The proposed standardised reporting and classification system was further developed by a sub-group of the project team. The proposed system was circulated for initial review to members of the Breast Imaging Reference Group (BIRG) of the RANZCR via State and Territory convenors in the Australian Capital Territory, New South Wales, Queensland, Victoria, South Australia, Tasmania and Western Australia. Further recommendations were provided by an additional workshop attended by 13 participants including State Convenors, BIRG members, and radiologists working in BreastScreen Australia and private practice. The sub-group considered all recommendations and revised the proposed standardised reporting and classification system accordingly.

## **Evaluation**

Recommendations about the reporting of breast imaging, and in particular about the use of a classification system, are a key aspect in the guide. The recommended classification system for breast imaging findings - a major component of the guide – is not currently used in Australia. Evaluation of the guide will therefore focus on its impact on the use of the classification system in breast imaging reporting.

A survey conducted approximately 12 months after the release of the guide will provide data on the use of the classification system in breast imaging reporting practice. This will identify the impact of the guide on reporting practice and may also identify opportunities to improve practice.

## SUMMARY

The following table provides a summary of the key recommendations presented in this document. All these recommendations should be considered in the diagnostic breast imaging of women. To understand each recommendation in context, please refer to the appropriate chapter.

	<b>Recommendation</b>	<b>Chapter</b>
IA	Mammography is the primary breast imaging modality for the investigation of symptomatic women 35 years and over, for the follow-up of women with a previous diagnosis of breast cancer, and for the screening of asymptomatic women aged 50–69 years.	I
IB	Ultrasound is the most common complement to mammography, and may be the primary and only imaging modality used for the investigation of breast symptoms in women less than 35 years and in women who are pregnant or lactating.	I
1C	The radiologist and radiographer should be informed about the location of the area of concern so they can include it on the mammogram and/or in ultrasound examinations.	I
2A	It is recommended that the triple test approach to the investigation of breast changes is used within the screening, assessment and diagnostic settings, and in the follow-up of women with a previous diagnosis of breast cancer.	2

	<b>Recommendation</b>	<b>Chapter</b>
2C	<p>The correct sequencing of tests in the triple test is important to the overall interpretation of the results and in the diagnostic setting should be:</p> <ol style="list-style-type: none"> <li>1. Medical history and clinical breast examination</li> <li>2. Imaging – mammography and/or ultrasound</li> <li>3. Non-excision biopsy – fine needle aspiration (FNA) cytology and/or core biopsy.</li> </ol>	2
2D	<p>Further investigation is required if the imaging results are not consistent with each other or with the history and clinical breast examination findings. This may include additional imaging and/or biopsy.</p>	2
3A	<p>Information relevant to the diagnostic imaging studies being performed must be obtained and recorded before the examination. An appropriately detailed request form will help ensure that the imaging report contains information of relevance to the referring clinician.</p>	3
4A	<p>It is essential that the woman remains central to the whole breast imaging process, is well informed in a timely and appropriate manner, and that her feelings and concerns are satisfactorily addressed.</p>	4
5A	<p>The referring clinician should inform the radiologist of any symptoms, the location and nature of palpable abnormalities, and results of relevant previous investigations so that the breast imaging studies can be tailored to answer the clinical question.</p>	5

	<b>Recommendation</b>	<b>Chapter</b>
5B	As a minimum, diagnostic mammography should include bilateral medio-lateral oblique (MLO) and cranio-caudal (CC) views.	5
5C	If clinical breast examination, ultrasound findings or FNA cytology/core biopsy results are equivocal, suspicious or malignant, bilateral mammography including the standard MLO and CC views should be performed, together with any additional images that the radiologist deems appropriate.	5
5D	In women with breast implants, mammographic imaging should include implant exclusion (Eklund) views in addition to the standard MLO and CC projections. The role of mammography and ultrasound in evaluating implant integrity is limited.	5
6A	Standardised reports have the potential to improve care for women and it is recommended that the 1–5 breast imaging classification system be used as part of every standard report: <ol style="list-style-type: none"> <li>1. No significant abnormality</li> <li>2. Benign findings</li> <li>3. Indeterminate/equivocal findings</li> <li>4. Suspicious findings of malignancy</li> <li>5. Malignant findings.</li> </ol>	6
7A	A system should be implemented to ensure that all imaging findings suggesting malignancy are immediately communicated to the referring clinician.	7



	<b>Recommendation</b>	<b>Chapter</b>
7B	Results should be provided to the woman as soon as possible, to help minimise her anxiety. It is preferable that results are given in person.	7
8A	A commitment to continuous quality improvement is highly desirable. It is recommended that RANZCR accreditation is sought by all diagnostic breast imaging services.	8
9A	It is recommended that all professionals involved in the provision of breast imaging services seek accreditation and continuing education from their governing professional organisation.	9
10A	New technologies should be rigorously evaluated and introduced in a planned and appropriate manner.	10

## CHAPTER I AN INTRODUCTION TO BREAST IMAGING

### Background

There are approximately 350,000 consultations for breast symptoms in Australia each year.<sup>23</sup> Diagnostic breast imaging, of which mammography is the most widely used method,<sup>24</sup> provides specific analytic evaluation of women with breast symptoms.<sup>13</sup> Ultrasound has also been established as a valuable diagnostic tool for both first-line imaging in younger women and as an adjunct to mammography.<sup>25</sup> With increasing awareness of the benefits of early detection of breast cancer, and prompt reporting of breast changes, there is likely to be an increase in the proportion of patients undergoing assessment of symptoms in whom a malignancy is not present.

In Australia, approximately 10,000 women are diagnosed with breast cancer each year<sup>26</sup> and over half of these are first found by the woman or her doctor as a breast change.<sup>27</sup> Cancer detection rates for symptomatic referrals to specialist breast clinics in Australia have been reported to range from 5–10%.<sup>28,29</sup>

The diagnosis of breast cancer relies upon a number of specialist skills provided by a multidisciplinary team. The benefits of a multidisciplinary approach to the management of women with breast cancer are well recognised.<sup>30–32</sup> While evidence for the benefits of a multidisciplinary approach to the assessment of breast abnormalities is limited, it is widely accepted that bringing together those with all the relevant expertise is the best approach to diagnostic management. Relevant expertise includes those responsible for the performance, interpretation and correlation of the tests and supportive care.

The triple test approach to the investigation of breast changes or symptoms involves clinical, imaging, and non-excision or percutaneous biopsy tests (see Chapter 2), and is the recommended approach to investigating breast changes or symptoms.<sup>25</sup> However, not all cases of benign breast changes will require biopsy and often the clinical impression can be confirmed by appropriate imaging. If the

triple test approach is used, a diagnosis should be achievable in the vast majority of cases without the need for excision biopsy.<sup>33</sup>

Imaging is a key component of the triple test. Between 1994 and 1996, approximately 1,086,000 unilateral and bilateral mammogram procedures and 545,000 ultrasound procedures were reimbursed through Medicare.<sup>34</sup> Between 1997 and 1999 the number of ultrasound procedures rose to over 800,000, while the number of mammograms decreased slightly to 1,030,153.<sup>35</sup>

### **General principles of breast imaging**

Breast imaging is used for the investigation of women with breast symptoms as well as for screening asymptomatic women. Clinicians are encouraged to refer asymptomatic women aged 50–69 years to the national mammographic screening program. Evidence from randomised trials demonstrated that mammographic screening could reduce deaths by up to 30% in women aged 50–69.<sup>36–38</sup> The benefit for women aged 40–49 is less clear.<sup>39</sup> Currently available data suggest that screening 10,000 women aged 50–69 over 10 years will prevent approximately 18 deaths, compared to preventing seven deaths in 10,000 women aged 40–49.<sup>40</sup> As a result, BreastScreen Australia targets women aged 50–69 and advocates two yearly mammographic screens, however women aged 40–49 and over 70 are also eligible to attend.

Apart from population screening, situations in which clinicians may wish to screen for occult cancer include women at high risk of developing breast cancer and those in whom a screening check to exclude evidence of cancer may inform management decisions – for example, an asymptomatic woman scheduled for breast reduction or augmentation surgery. The use of breast imaging in women at high risk should be in accordance with agreed national guidelines, where they exist. High-risk groups include women with a:

- previous diagnosis of invasive breast cancer<sup>41</sup>
- previous diagnosis of ductal carcinoma in situ (DCIS)<sup>42</sup>
- previous diagnosis of lobular carcinoma in situ (LCIS) or atypical hyperplasia (AH)<sup>42</sup>
- strong family history of breast cancer.<sup>43</sup>

## Use of mammography

Mammography is the primary breast imaging modality for the investigation of symptomatic women 35 years and over, for the follow-up of women with a previous diagnosis of breast cancer and for the screening of asymptomatic women (see Appendix B). A mammogram gives a two-dimensional radiographic representation of most (and sometimes all) of the breast tissue. Abnormalities in the breast can be categorised as:

- Mass lesions
- Asymmetric densities
- Architectural disturbances
- Calcifications
- A combination of these.

Various features, such as shape and border characteristics, are used to further analyse these findings and to propose provisional diagnoses. For optimal diagnosis, a mammogram must be well positioned and of high contrast and spatial resolution.

The standard mammographic examination includes two views, medio-lateral oblique and cranio-caudal. The views describe the position of the breast and the angle of the X-ray beam. Correct positioning of the breast requires considerable radiographic skill, as the breast tissue must be pulled away from the chest wall and onto the film, and positioned and compressed appropriately. Well positioned films allow ready evaluation of the symmetry of the two breasts and comparison with previous films. Additional views may be used to better display specific areas of the breast. For example, the *cleavage view* shows medial breast tissue and the *Cleopatra view* shows the axillary tail tissue. The accuracy of mammographic diagnosis is further improved by the use of the specific mammographic techniques of coned compression and microfocus magnification, or a combination of both. These specific techniques give better contrast and spatial detail but visualise only the targeted area of radiographic interest rather than the whole breast. Accordingly, the examination can be tailored to a specific clinical problem by the use of special views and techniques.

The proper use of dedicated mammographic equipment is essential for obtaining high-quality images. It is important that optimal film and equipment are used, appropriate exposure parameters and processing techniques are selected, and quality control standards are adhered to. Proper quality assurance measures ensure that low radiation doses are used, and that unnecessary radiation exposure is avoided. The risk of breast cancer development associated with modern mammographic techniques is estimated to be extremely small.<sup>44</sup>

The sensitivity of mammography for detecting any abnormality will depend upon:

- The nature of the breast lesion
- The radiographic density and overall nodularity of the breast tissue
- The location of the abnormality within the breast
- The technical quality of the mammograms
- The radiologist's expertise in interpreting the imaging appearances.

Lesions that are calcified, that distort breast tissue or that have definite borders are easier to perceive than poorly defined, low-contrast lesions. The more dense or nodular the breast tissue, the more difficult it can be to detect lesions that are non-calcified or that do not distort tissue. Subareolar lesions may be difficult to perceive. Lesions that are very high on the chest wall, very deep within the breast or very far medial may be difficult to image on standard projections and may require special views for imaging. It is imperative therefore that the radiologist and radiographer know the location of the area of concern and are able to include it on the mammograms.

### **Use of ultrasound**

Even with excellent quality mammography technique and interpretation, a lesion may not be visible on the mammogram or the mammographic findings may be indeterminate. Other imaging modalities such as ultrasound may be necessary for complete imaging evaluation. Ultrasound is the most common complement to mammography and may be the primary and only imaging modality used for the investigation of breast symptoms in women less than 35 years. Ultrasound is the preferred initial imaging technique in women who are pregnant or lactating.<sup>25</sup>

Ultrasound may be used in a complementary capacity to mammography:

- In the evaluation of palpable lesions not seen on mammography
- For improved benign/malignant differentiation of mammographic lesions
- For detection of associated underlying mass or altered architecture associated with mammographic calcifications or asymmetric density
- For implant evaluation
- As a guidance technique for non-excision (percutaneous) biopsy or pre-operative localisation.

As with mammography, the ability to detect an abnormality with ultrasound depends upon the quality of the equipment, the skill of the operator, the nature of the abnormality, the type of breast tissue and the clinician's skill in interpretation. High image contrast and spatial resolution are critical for optimal ultrasound diagnosis. The ultrasound equipment must have good near-field resolution with a high-megahertz transducer and pre- and post-processing that optimises breast tissue image characteristics.

The operators ability to recognise normal tissue appearances and to differentiate these from subtle abnormal changes is crucial to making a diagnosis. Unlike mammography, which displays most of the breast tissue on a single image, ultrasound examination will only display thin slices or portions of the breast tissue on any one image. It is most effectively used when the examination is targeted to an area of concern, that is, an area of clinical or mammographic abnormality. It is generally easier to detect mass lesions in dense breast tissue with ultrasound than with mammography. Where lesion/s produce distortion, posterior acoustic shadowing or enhancement, perception is also easier. Calcifications may be identified within masses or altered soft tissues, but can not be seen unless sufficient in number/size.

It is important that the ultrasound findings are correlated with mammography and clinical findings. Ultrasound has the advantage of allowing direct correlation of palpable and imaging features during the course of the ultrasound study.

Occasionally it is difficult to be certain that a non-palpable ultrasound lesion is the same as a mammographic abnormality. In this situation, needle placement or contrast injection under ultrasound guidance with repeat mammograms may be necessary for confirmation.

Ultrasound is not advocated as a screening tool, because:

- Ultrasound examination images only a small area of breast tissue at a time
- Mass lesions are difficult to identify in fatty-replaced breasts
- Microcalcifications are not reliably imaged.

There may be a role for ultrasound in the screening evaluation of high-risk women with dense breast tissue, but this has not yet been proven. However, incidental and equivocal findings are detected at a high rate with ultrasound screening. This can lead to an increase in the requirement for further investigations, including non-excision biopsies.

### **Combined use of mammography and ultrasound**

Given the limitations of both mammography and ultrasound, they are often used in conjunction to give complementary information in the evaluation of breast abnormalities. It is particularly important to note that false negative diagnoses can occur with both techniques.

False negatives can be minimised by:

- Ensuring the technical aspects of the imaging examination are of good quality
- Knowing the clinical indication for the imaging
- Directing the imaging to the area of interest with special mammographic views and (in the case of ultrasound) viewing this targeted imaging in real time
- Carefully correlating the imaging appearances with the clinical findings
- Maximising the radiologist's diagnostic accuracy through appropriate training and expertise in image perception of abnormalities and analysis of imaging features.

Occasionally other imaging modalities may be required for the complete evaluation of breast symptoms. The most widely used technique is magnetic resonance imaging (MRI). Chapter 10 provides information about other imaging modalities.

Both ultrasound and mammographic stereotactic localisation may be used to guide FNA and/or core biopsy of lesions in the breast as well as pre-operative localisation.

### **Summary points**

- As with mammography, the ability to detect an abnormality with ultrasound depends on the quality of the equipment, the skill of the operator, the nature of the abnormality, the type of breast tissue and the clinician's interpretive skill.
- The proper use of dedicated mammography equipment is essential for high-quality images. It is important that optimal film and equipment are used, appropriate exposure parameters and processing techniques are selected, and quality control standards are adhered to.
- High image contrast and spatial resolution are critical for optimal ultrasound diagnosis. The ultrasound equipment must have good near-field resolution with a high-megahertz transducer and pre- and post-processing that optimises breast tissue image characteristics.



## CHAPTER 2 THE CONTEXT FOR BREAST IMAGING

### The triple test approach to diagnosis

The triple test is the recommended approach to maximise diagnostic accuracy in the investigation of breast changes, within the screening and diagnostic settings and in the follow-up of women with a previous diagnosis of breast cancer. The triple test refers to three diagnostic components:

- Medical history and clinical breast examination
- Imaging – mammography and/or ultrasound
- Non-excision biopsy – fine needle aspiration (FNA) cytology and/or core biopsy.

The triple test is described in detail in the Centre’s publication, *The investigation of a new breast symptom: a guide for general practitioners*.<sup>25</sup>

The term ‘triple test’ refers to the three fundamental components that make up the investigative pathway used to assess breast changes. However, it does not mean that every woman requires *all* three tests in every case. The effective use of breast imaging, mammography with or without ultrasound, is a key aspect of the triple test, and in *some* cases may eliminate the need to proceed with further tests.

The correct sequencing of tests is important to the overall interpretation of the results.<sup>25</sup> Diagnostic imaging should only be performed after an adequate medical history has been taken and a thorough clinical breast examination performed. Where possible, imaging should be performed before any diagnostic sampling such as FNA cytology or core biopsy is undertaken.<sup>25</sup>

Performing clinical breast examination and imaging before diagnostic sampling helps ensure that sufficient information is obtained about the size, extent, and characteristics of the area of interest before any possible disturbance or distortion of the tissue by the biopsy or possible resultant haematoma. Imaging studies may also help determine the most appropriate sampling procedure and may affect the

number of sites to be sampled. They may also determine the best biopsy approach, by providing information about the depth and composition of the lesion/area of interest and the nature of the surrounding tissue.

The triple test aims to:

- Optimise the diagnostic accuracy in breast disease
- Maximise the pre-operative diagnosis of cancer
- Minimise the proportion of excision biopsies for diagnostic purposes.

The sensitivity of the triple test is greater than any of the individual components alone. The likelihood of cancer increases if more than one component is positive that is, suspicious or malignant.<sup>25</sup> Although the results of diagnostic imaging may provide specific and clinically valuable information, they should not be interpreted in isolation. The results of each of the components of the triple test should be collated, reviewed, and interpreted in view of all other test results.

The triple test is regarded as positive if *any* of its three components are positive, and as negative if *all* three components are negative. In the diagnostic setting, the sensitivity of the triple test is 99.6% – that is 99.6% of cancers would have a positive test result.<sup>45</sup>

In cases where cancer is detected, such an approach allows for pre-operative discussion of treatment options and counselling with the woman, and assists in the planning of single-stage surgery.<sup>46,47</sup>

In cases where a benign diagnosis is confirmed and the need for further investigation or excision biopsy is eliminated, the woman can be reassured and appropriate further management options discussed.

### **Clinical perspectives of what is required from breast imaging**

Diagnostic imaging should aim to answer the clinical query. Breast imaging may be used for a variety of reasons and it is important to differentiate the clinical perspectives of what is required from each case.

When referring a woman for breast imaging, clinicians should provide all relevant information on the imaging request form and indicate the imaging modality most appropriate to the case. While the referral should indicate the imaging modalities requested, it may be appropriate to allow the radiologist to tailor the imaging to the individual circumstances. Advice from the radiologist should be sought by the referring clinician when necessary. Information about requesting breast imaging is contained in Chapter 3 and an example request is form provided in Appendix C.

A benign result can be expected for most imaging tests, since the majority of breast changes are benign. However, it is important that the test results are reviewed and collated to ensure the consistency of results and thus optimise diagnostic accuracy. Benign imaging findings may not necessarily correlate with the clinical findings. Any suspicious test requires further investigation, even when other tests indicate a benign finding.

### *Approach to diagnosis*

For the referring clinician, diagnostic imaging provides another ‘piece of the puzzle’ in the diagnostic pathway. The results of breast imaging, together with the clinical breast examination and medical history, should be reviewed for consistency and to determine whether further investigation is needed. The following is a guide to the management of common diagnostic situations:

- If the normal or benign imaging results are consistent with the history and clinical breast examination findings, no further investigations may be indicated
- If the imaging results are not consistent with each other or with the history and clinical breast examination findings, further investigation is required. This may include additional imaging and/or biopsy
- If either the result of imaging or clinical breast examination is suspicious or malignant, further investigation and referral to a specialist surgeon is required – regardless of a normal mammogram or ultrasound.

### *Case 1*

*A 30-year-old nulliparous woman presents with a discrete, smooth 1 cm firm, mobile lump medially in the right breast that has become apparent in the past week. History and clinical breast examination support the diagnosis of a benign lesion, such as a cyst. The clinician arranges an ultrasound, expecting it to show the typical features of this, in which case the patient can be reassured. The ultrasound reveals atypical features.*

*Further investigation is required: mammography and FNA cytology or core biopsy (preferably under image guidance).*

Imaging tests are often used to compliment other tests in order to maximise the amount of information about the area of interest. If the investigation requested does not answer the clinical question, is not the most appropriate test or does not provide adequate information, the radiologist may recommend a further or more appropriate test. Good communication between the requesting clinician and the radiologist will facilitate this process. For example, in Case 1 above it may be considered both clinically appropriate and expedient for the radiologist to proceed with the image guided biopsy at the initial visit. However, where an invasive or costly test is recommended this should *only* be performed if indicated on the referral form or after prior discussion with the referring clinician and *most importantly* with the informed consent of the woman.

A description of the radiological or sonographic position and features of any lesions will assist the referring clinician to collate the clinical, radiological and pathological findings and determine a diagnosis and management plan. The description generally includes documentation of the site (using clock-face and distance from the nipple in millimetres) size and composition of the lesion/s, relationship to surrounding stroma, architectural features, any other identifying features seen and a diagnosis if possible. Even if imaging appearances are not diagnostic, a detailed description of the area of interest is helpful in providing baseline information with which results from past and future imaging studies can

be compared. The use of a standardised report has been shown to facilitate this process.<sup>48-51</sup> Standardised reporting is discussed in further detail in Chapter 6.

### *Planning surgical treatment*

Following a diagnosis of breast cancer, the imaging can be reviewed to assist in planning treatment. For example information from imaging detailing the size and extent of the lesion, proximity to the chest wall and nipple and associated findings can be used in conjunction with clinical and biopsy findings to assist in deciding on the appropriateness of breast conservation versus mastectomy.

Consideration should be given to the recommendations in the *Clinical practice guidelines for the management of early breast cancer: 2<sup>nd</sup> edition*,<sup>41</sup> and *Clinical practice guidelines for the management of advanced breast cancer*.<sup>52</sup>

Communication between the clinician and radiologist is essential to ensure the correct interpretation of the imaging.

#### *Case 2*

*A 66-year-old woman presents with a 1 cm hard mass lesion in the axillary tail of the left breast. The mass is tethered to the skin. If the mass lesion is confirmed histologically to be breast cancer, it may be completely locally excised with an acceptable cosmetic result.*

Mammography and/or ultrasound will assist in identifying whether there is more than one abnormality in the breast. Imaging will show the margins of the breast mass and whether any microcalcifications (with malignant or benign radiological features) or other impalpable changes are confined to, or extend beyond, the mass lesion. The imaging may also indicate other areas that require investigation.

#### *Case 3*

*A 66-year-old woman presents with a clinically large breast cancer which is not suitable for local excision. Initial systemic therapy may be used to reduce the size of the cancer before definitive local therapy.*

In this case, baseline breast imaging will document the initial size of the tumour against which subsequent imaging could be compared.

### *Planning radiotherapy treatment*

Radiation oncologists generally see women in whom a diagnosis of breast cancer has already been made, and have special requirements from breast imaging related to the planning of radiotherapy treatment. The availability of a clear description of the cancer by the radiologist, in conjunction with the histology details, will assist the oncologist in planning radiotherapy to the breast following breast conservation surgery. The radiation oncologist needs to work in association with other members of the multidisciplinary team.<sup>53</sup>

If radiotherapy to the whole breast and a ‘boost’ of radiation to the tumour bed is to be given, the original position of the cancer, its size and the depth between the skin and chest wall will help determine the margins of the radiotherapy fields, particularly for the ‘boost’. Positioning of the patient during radiotherapy differs from the positioning required for mammography and/or ultrasound examination. The radiation oncologist must consider this when determining the radiotherapy boost field. The placement of radio/opaque markers in the breast tumour bed at the time of surgery can improve the accuracy of radiotherapy breast field placement.<sup>54,55</sup> Ideally, the imaging report should be considered together with the pre-operative clinical description of the cancer, the surgeon’s operative report and examination of the patient after surgery.

### *Follow-up after treatment for early breast cancer*

Of the approximately 10,000 women diagnosed with breast cancer each year<sup>26</sup> in Australia around 5 – 10% will have developed a local recurrence in the conserved breast at 5 – 10 years.<sup>56</sup> The recommended follow-up after initial treatment for early breast cancer is regular clinical breast examination and annual mammography, with or without ultrasound as required.<sup>41,57–59</sup> This follow-up is used to detect recurrence in the conserved breast and any new abnormalities in the conserved or contralateral breast.

Imaging of the treated breast may be difficult to interpret, as recurrence can mimic post-surgery and radiotherapy changes. In one study of 135 patients, mammography of the conserved breast 12 months after surgery revealed architectural distortion in 82% of patients increased density in 79% and skin thickening in 54%. The incidences of mass lesions and calcifications were 12% and 3% respectively.<sup>60</sup> When serial mammography is undertaken over several years, density due to oedema resolves but scars and fibrosis remain, although their extent generally reduces with time.<sup>60</sup>

Routine imaging of the chest wall after total mastectomy is not required, but both mammography and ultrasound may be appropriate if local recurrence is suspected clinically. Mammography may not be feasible in the absence of adequate skin laxity on the chest wall.

The most common features of a local recurrence include a new mass lesion or microcalcifications.<sup>61</sup> The mammographic features of a breast recurrence are often similar to the features identified on the original pre-treatment mammogram, and this can be a helpful clue to recurrence.<sup>62</sup> Progress mammograms with or without ultrasound should always be correlated with pre-treatment imaging studies.

The following case history illustrates possible findings during follow-up.

#### *Case 4*

*A 66-year-old-woman has undergone a wide local excision of her cancer with clear surgical margins, has had radiotherapy to the breast and attends at her third anniversary for routine follow-up. On clinical breast examination, there is firmness around the breast scar and a tender 1 cm area at the lateral end of the scar. Mammography with coned magnification views shows a well defined 1 cm lesion with a rim of calcification and a lucent central area. Ultrasound shows the central area to be cystic. Comparison with imaging performed at first and second anniversaries demonstrates that the features are consistent with a scar and a developing oil cyst with dystrophic calcifications.*

Very little data is available to guide the frequency of post treatment imaging, or indeed when the first imaging studies should be performed post treatment.<sup>63</sup> The irradiated breast is generally oedematous and tender for around six months after radiation, making mammography before this time uncomfortable. The median time to development of a breast recurrence is around 36 months, with very few recurrences occurring before 12 months.<sup>56,62</sup> This suggests it is reasonable to wait six or even 12 months after breast surgery before performing the first post-treatment mammogram. The Centre's *Clinical practice guidelines for the management of early breast cancer: 2<sup>nd</sup> edition*<sup>41</sup> recommends mammography (with or without ultrasound as required) at six to 12 months after radiotherapy for conserved breasts, at 12 months after mastectomy, and annually thereafter.

Recommendations for imaging follow-up for women with ductal carcinoma in situ (DCIS), lobular carcinoma in situ (LCIS) and atypical hyperplasia (AH) are provided in the *Clinical practice guidelines for the management of ductal carcinoma in situ, lobular carcinoma in situ and atypical hyperplasia of the breast* (in preparation).<sup>42</sup> In the case of DCIS, the guidelines recommend that follow-up by mammography with magnification may be helpful if there is doubt about the margins at excision and that this may be performed after a few weeks. Routine mammographic follow-up of the treated breast should begin six to 12 months after treatment, with magnification views of the excision site to assess residual or new microcalcification. Thereafter, annual bilateral mammography is recommended with magnification views when indicated.

In the case of LCIS and AH, it is recommended that imaging follow-up is lifelong annual bilateral mammographic screening and annual clinical breast examination commencing from the time of histologic diagnosis.<sup>42</sup>

#### *Follow-up after breast reconstruction*

Although recurrent and metastatic breast cancer have been reported within reconstructed breasts,<sup>64-67</sup> routine imaging of the reconstructed breast is unnecessary because the incidence of malignancy is low and post-reconstruction



imaging is difficult to interpret. However, both mammography and ultrasound may be indicated if there is clinical suspicion of recurrent or metastatic disease.

### *Follow-up for benign outcomes*

When the investigation of a breast change identifies a benign outcome, follow-up imaging may be advised for some women, such as those with a significant family history. To help the women understand why follow-up is necessary, provision of information and full discussion of her concerns are recommended. A tool for assessing whether a woman is at increased risk of developing breast cancer due to family history is provided in Appendix D. Chapter 4 provides information about preparing women for breast imaging.

### **Summary points**

- The sensitivity of the triple test is greater than any of the individual components alone.
- Imaging has an important role in the follow-up of women after treatment for breast cancer and in the follow-up surveillance of women at high risk for breast cancer.

## CHAPTER 3      REQUESTING BREAST IMAGING

A full clinical assessment should be made before any referral for diagnostic breast imaging. This includes taking a relevant medical history and performing a thorough clinical breast examination. The initial consultation is also an appropriate time for the clinician to provide information to the woman and address any concerns, irrespective of whether a referral for breast imaging is deemed necessary.

The first step to achieving good communication between the referring clinician and radiologist is to use the request form effectively. An easy to read, well-prepared, legible request form will help to ensure that the imaging report contains information of relevance to the referring clinician and that appropriate tests are performed. A legible and easy to read request form may also help the radiologist to meet the requirements of the referring clinician.<sup>68,69</sup>

In order to determine the appropriateness of different imaging tests, the referring clinician should be familiar with the indications for and limitations of each imaging modality (Chapters 1 and 5). In many cases the choice of test/s may be left to the discretion of the radiologist, and the request form should provide for this. For example, the referring clinician may request mammography with ultrasound as optional, allowing the radiologist's discretion in optimising diagnostic accuracy.

The Health Insurance Commission guidelines indicate that no specific format is required for request forms, but that they must state the service requested, be dated and include the name and address or name and provider number of the requesting practitioner.<sup>70</sup> Most radiological practices have their own request forms that include generic fields such as the practice address, patient identification details, clinical information, test/s required, whom the report should be sent to, the urgency of the request and the preferred method of relaying the report. The Royal Australian and New Zealand College of Radiologists (RANZCR) recommends in its *Accreditation standards for diagnostic and interventional radiology*<sup>5</sup> that

information relevant to the studies being performed must be obtained and recorded before the examination. In the context of diagnostic breast imaging this information may include pregnancy status and previous studies.

In addition, clinicians should include on the request form relevant clinical information that may affect the appearances of the images or their interpretation, such as:

- Past history of breast surgery for benign or malignant disease
- Past history of breast reduction or augmentation
- Previous radiotherapy
- Significant findings on previous breast imaging.

Specific information relating to the area of interest should include the side, size and location within the breast. A clock-face description and the distance from the nipple in centimetres, with or without an indication of the depth beneath the surface, are conventional. Providing a diagram on the request form for schematic representation will also assist to localise the area of interest. Referring clinicians are encouraged to also provide a clinical impression or differential/provisional diagnosis in the clinical notes.

Women should be encouraged to bring in their previous imaging films, which may be useful for the radiologist and referring clinician, particularly in difficult assessment cases.

Specific questions should be asked if comments are sought in the report, such as, *'Has the mass changed in size since previous breast imaging'* Previous breast imaging films or reports should always be made available in these situations. Specific action by the radiologist may also be requested, such as *'If mass is consistent with abscess, please perform FNA biopsy or core biopsy'*. In this case it is important to inform the woman of the possibility that a FNA biopsy may be carried out by the radiologist.

An example of a request form is provided in Appendix C. This is meant to serve as a checklist of desirable information to include on a request form and may not reflect what is normally available to the referring clinician. The example form may be used to ensure that adequate information is included on all requests for breast imaging. For instance, a generic radiology request form can be tailored to breast imaging by using a rubber stamp imprinted with a schematic diagram of breasts, to enable identification of the area of interest.

### **Summary point**

- A high-quality request form will help to ensure that appropriate tests are performed and that the imaging report contains information of relevance to the referring clinician.

## CHAPTER 4      PREPARING WOMEN FOR BREAST IMAGING

### **Effective communication**

Many women will experience breast changes that are normal, for example due to aging or hormonal variations. The vast majority of imaging test results are therefore normal or benign, with approximately 95% of breast changes due to causes other than breast cancer.<sup>9</sup> However, what is a straightforward and a commonplace test to the clinician is often a very anxiety-provoking experience for the woman, irrespective of whether the result is benign or requires further investigation.<sup>17-22,71-77</sup>

It is essential that the woman remains central to the whole breast imaging process and that her feelings and concerns are satisfactorily addressed. The clinician should adopt a friendly and sympathetic manner, acknowledge and respect her emotional concerns, and encourage her to express these if she wishes. For instance, the woman can be told that a friend or other support person may accompany her during the breast imaging examination if she wishes.

To maximise the woman's satisfaction with the overall breast imaging experience irrespective of the outcomes of the tests, it is important she is informed of her results in a timely and appropriate manner and is provided with an accurate diagnosis in the minimum amount of time. There is strong evidence that providing women with information about the procedure that they are about to undergo reduces their emotional distress and improves their psychological and physical recovery.<sup>78</sup>

The clinician's communication skills are of paramount importance in helping to alleviate anxiety that the woman may experience during the assessment of a breast change. Effective communication involves more than providing information: it is critical to tailor the explanation to each individual woman and acknowledge her needs and concerns. The clinician initiating the diagnostic process should ensure that the woman is satisfied with, and understands, the information she has received. This may be achieved by checking with the woman

what she understands about her breast change and the reasons for having the breast imaging, and asking how much information she would like to receive.<sup>78</sup>

Information is most effectively communicated verbally face to face by the health professional, and may be supplemented by written, audio or other resources as appropriate.<sup>78</sup> For example, the Centre's booklet *Breast changes*<sup>9</sup> is a useful resource for referring clinicians to give the woman to facilitate her understanding of the tests that may be performed. However, written information should always be used to supplement information communicated verbally by the referring clinician, radiologist, radiographer or sonographer, and not as a substitute.<sup>20</sup> Guidance for clinicians is provided in *Psychosocial clinical practice guidelines: information, support and counselling for women with breast cancer*.<sup>78</sup> A summary of the relevant sections of these guidelines is included in Appendix E.

### **Providing information**

The referring clinician may wish to discuss verbally the following topics with the woman, and provide supplementary written information:

The rationale for diagnostic imaging, including:

- When mammography or ultrasound are used, and what information they can provide
- How imaging provides one component of the triple test. The Centre's *Breast changes*<sup>9</sup> booklet and/or *Do you have a breast change?*<sup>79</sup> information sheet may assist in explaining the diagnostic process
- The likelihood that the breast change could be cancer. It may be appropriate to discuss factors such as age, history of previous benign/malignant symptoms and family history to help a woman understand the need for further tests
- The possibility that additional images or special views may be taken to improve the picture quality or accuracy of targeting the area of interest. This may be particularly necessary if the woman has had previous diagnostic or therapeutic breast surgery or radiotherapy to the breast
- The possibility that FNA cytology or core biopsy may be carried out by the radiologist.

Proposed imaging mode/s, including:

- Why the particular imaging technique or combination of imaging techniques has been selected
- A description of the mammography and/or ultrasound procedure, and what it involves
- Possible sensations during the procedure – such as what is seen, felt or heard and the likelihood of pain or discomfort
- The accuracy and limitations of the tests. It is important to ensure that the woman understands that other tests may be required to confirm a diagnosis.

Practical arrangements for referral, including:

- The availability of different diagnostic imaging venues
- The woman's transportation needs
- The financial circumstances of the woman, payment advice and cost of the procedure
- The woman's physical needs or other personal circumstances
- Appointment details, how to make an appointment, and the name and address of the radiology clinic.

Practical arrangements for the tests, including:

- How long the procedure will take
- What to wear – ie a two-piece outfit to enable easy removal of clothing on the upper body
- Encouraging the woman to bring along a support person if she wishes
- The need to bring any previous imaging films.

Practical arrangements after the tests, including:

- When and how the woman will be provided with the test results. A discussion of communicating results is included in Chapter 7
- The possibility that further tests may be required to obtain a final diagnosis
- Possible outcomes and what future appointments, tests or referrals may be required.

Additional issues, including:

- Encouraging the woman to express any other concerns she may have, such as the possibility of cancer, time off work, the need for treatment and its effectiveness, or other issues surrounding cancer
- How to access further information, for example – provide names of organisations, resources or Internet sites.

### **Summary points**

- The provision of accurate and timely information can help a woman prepare for diagnostic imaging and reduce her anxiety.
- The relevant clinician should communicate the information verbally and supplement the discussion with written or other resources.
- The woman should be informed about what the tests will involve, the accuracy and limitations of the tests and what the results may mean.



## **CHAPTER 5      TAILORING THE BREAST IMAGING EXAMINATION**

### **Imaging the asymptomatic woman**

For women aged 40 years and over the BreastScreen Australia Program provides screening mammography free of charge. While only women aged between 50–69 are actively targeted, women aged 40–49 and over 70 are also eligible to attend. If there is a mammographic abnormality suggestive of breast cancer, the woman is recalled to an assessment centre for evaluation by a multidisciplinary team.

Breast cancer is less common in women aged less than 40 years. While there is evidence that mammographic screening may reduce deaths by up to 30% in women aged 50–69,<sup>36–38</sup> the benefit for women aged 40–49 is less clear.<sup>39</sup> Routine imaging is not recommended in women aged less than 40. If a young woman is increased risk of breast cancer because of her family history (see Appendix D) or other risk factors, mammographic screening may be indicated. Although promising, the long-term value of mammography in this setting is unclear.<sup>80</sup>

### **Imaging the symptomatic woman**

In order to tailor the breast imaging studies to answer the clinical question the radiologist must be aware of any symptoms, the location and nature of palpable abnormalities, and results of relevant previous investigations. Many women do not know the location or nature of a palpable abnormality or biopsy results and cannot provide this information for the radiologist.

The role of the radiologist is to select the appropriate imaging tests, monitor and tailor the examination as it is being performed, interpret the studies, ensure that the clinical questions are addressed and make appropriate recommendations to the referring clinician. It is important that the radiologist obtains all required studies at the time of the woman's visit and avoids recalling her for additional views or another examination. It is helpful if the referral indicates whether selection of mammography and/or ultrasound may be made at the radiologist's discretion, as the referring doctor is not always available to approve further procedures at the time of mammography. The ability to perform FNA cytology

and/or core biopsy at the time of the initial radiology consultation may also expedite management but this procedure should only be performed with the appropriate referral from the clinician and informed consent of the woman. It is the responsibility of the radiologist to ensure that the most appropriate imaging or interventional procedures are undertaken.

The radiologist is also responsible for ensuring the technical quality of the imaging procedures. Technical parameters and quality-assurance procedures are beyond the scope of these guidelines but are detailed in the RANZCR *Diagnostic Mammography Standards*<sup>3</sup> and in the *National Accreditation Standards for the BreastScreen Australia Program*.<sup>2</sup>

Imaging films should be clearly labelled to meet clinical and medico-legal standards. The RANZCR's *Accreditation Standards for Diagnostic and Interventional Radiology*,<sup>5</sup> the RANZCR's *Mammography Standards*<sup>3</sup> and the *National Accreditation Standards for the BreastScreen Australian Program*<sup>2</sup> all include standards for the labelling of imaging films. The RANZCR's requirements for the labelling of imaging film are outlined in Appendix F.

The selection of the most appropriate imaging procedure for the symptomatic woman is dependent on her age and the type of symptom. A range of scenarios is discussed in detail, and a summary of the imaging options from *The investigation of a new breast symptom: a guide for general practitioners*<sup>25</sup> is provided in Appendix B.

*Imaging the symptomatic woman aged less than 35 – palpable abnormality (mass or thickening)*

The majority of symptomatic women aged less than 35 do not have breast cancer. The role of imaging is to determine the nature of the palpable lesion, using ultrasound as the initial imaging modality of choice.<sup>81–83</sup> For lesions that are benign on clinical and ultrasound examinations, no further evaluation may be necessary. FNA cytology or core biopsy can be performed to confirm the normal or benign nature of the palpable abnormality.<sup>25</sup>

If clinical breast examination or ultrasound findings are equivocal, suspicious, or malignant, bilateral mammography including the standard medio-lateral oblique (MLO) and cranio-caudal (CC) views should be performed as well as any additional images that the radiologist deems appropriate. The purpose of mammography in this instance is to provide additional information about the lesion, to determine the extent of any malignancy and to evaluate the opposite breast by screening for any clinically occult cancer prior to needle biopsy, surgery or other treatment.

*Imaging the symptomatic woman aged 35 and over – palpable abnormality (mass or thickening)*

Breast symptoms are common in this age group, but even above the age of 35 most symptomatic women do not have breast cancer.<sup>84</sup> However, the risks of both symptomatic and occult breast cancer increases with the increasing age of the women. Mammography is the imaging modality of choice.<sup>81</sup> The role of imaging is to define the palpable abnormality and to detect any clinically occult breast cancer that may be present in either breast. If the clinical or mammographic findings are suspicious for malignancy, it is important to also search for evidence of other findings that may indicate spread beyond the area of clinical suspicion.

As a minimum, the mammographic examination should include MLO and CC projections of each breast. Additional images may be performed as directed by the radiologist. Compression spot views of the area of interest are commonly used. It is possible to achieve better compression of a small area of the breast and thus better definition of a lesion through reduced scatter, improved contrast and better displacement of overlying tissues. If a lesion is seen on only one view, additional images should be performed for complete localisation. These images may include extended CC images, 90-degree mediolateral or lateromedial images, tangential views or a series of compression spot images. Occasionally, more innovative positioning is required.<sup>85–88</sup>

Ultrasound can be helpful in evaluating symptoms and may be performed in order to further characterise lesions demonstrated by mammography and to detect palpable abnormalities not seen on mammograms.

FNA cytology and core biopsy may be used to prove the benign nature of a lesion, to aid in the management of patients with indeterminate lesions, or to confirm the diagnosis of malignancy for pre-operative planning. Even with a palpable lesion imaging is useful for guidance to ensure that the needle is properly positioned within the particular lesion that is to be sampled, thus minimising the chance of sampling errors.<sup>89,90</sup>

*Imaging the symptomatic woman – pain or focal area of tenderness as only symptom or sign*

Breast pain is a very common symptom. In the absence of other clinical findings, pain alone is infrequently associated with imaging abnormalities and very uncommonly is a presenting symptom of breast cancer. The role of imaging in this situation is either to identify the occasional lesion that might be the cause of breast pain, or where no malignancy can be identified to reassure the woman that this is the case.

As a guide, the imaging of focal areas of pain is the same as for palpable masses – that is, mammography with or without ultrasound in women aged 35 and over, and ultrasound for women aged less than 35. In addition to identifying benign discrete masses, imaging may indicate the cause of pain to be areas of inflammation/oedema/fat necrosis, a tender cyst, or superficial venous thrombosis (Mondor's syndrome).

*Imaging the symptomatic woman with nipple inversion or discharge*

Many women will notice spontaneous or expressed nipple discharge at some point in their life, and nipple flattening and inversion is common in older women. The likelihood of an underlying malignancy associated with nipple discharge varies with the nature of the discharge, the age of the woman, and whether or not there are palpable masses.<sup>91</sup> Careful clinical breast examination and medical history are important in the evaluation and management of these women. Serous and bloody nipple discharges, and discharges produced by a single duct, are more likely to be associated with cancer than yellow, white or green discharges.

Women over 60 years with a discharge are more likely to have cancer than younger women.

The purposes of imaging are to:

- Detect an associated malignancy or benign discrete mass
- Identify the duct/s that may be producing the discharge.

Mammography is most useful in the detection of an underlying malignancy. Occasionally a papillary lesion may become large enough to produce a mass on mammography. In addition to the routine MLO and CC images, a magnification compression spot view of the subareolar area may be helpful.

As well as further evaluating masses seen on mammography, ultrasound is useful in identifying dilated ducts and may detect intraductal lesions. Ultrasound can be used to guide FNA cytology of an intraductal lesion, but this is usually not helpful unless the lesion has suspicious imaging features. Although it is technically possible to perform FNA cytology on intraductal papillary lesions that are imaged by ultrasound, these will require surgical excision for complete evaluation. Cytology of a discharge is helpful only if positive for cancer – a benign result does not necessarily exclude malignancy due to the high false negative rate of approximately 50%.<sup>91,92</sup>

Galactography is occasionally useful in evaluating nipple discharge.

Galactography is not required to guide clinical management in the majority of cases, and is usually performed at the request of the surgeon. If the discharge emanates from a single duct orifice, galactography can be used to identify an intraductal lesion or to demonstrate the course of the duct as a guide to surgery. Galactography is possible only when the discharge can be expressed. A cannula is placed into the duct, water-soluble contrast is injected, and mammograms are obtained to demonstrate the contrast-filled duct. The technique demonstrates the course of the duct and its branches, together with any irregularities of the duct, obstructing lesions and filling defects. False-positive diagnoses can occur with intraductal debris simulating masses.

### *Imaging the symptomatic woman with inflammation or abscess*

Most women with inflammation or an abscess respond to medical treatment and do not require imaging. If imaging is required, ultrasound is the most helpful modality for monitoring response to treatment, identifying fluid collections to be drained and providing imaging guidance for drainage.

The role of mammography is to detect cancer, and it is usually performed when inflammation is not responding to usual treatment. However the breast may be difficult to compress in the presence of inflammation and the quality of the mammographic image may be compromised. The area of concern may also be radiographically quite dense, further compromising evaluation. Ultrasound may be useful in this situation.

### **Imaging the pregnant/lactating woman with a mass**

Imaging of pregnant or lactating women is the same as for women aged less than 35. Ultrasound is the examination of choice for evaluating any mass and for guiding non-excision (percutaneous) biopsy, if necessary. If there is suspicion of cancer, then mammography should be performed with any additional images that are required to fully evaluate the lesion. Pregnancy is not an absolute contraindication for mammography. Although the low kilovoltage used does not have sufficient penetrating power to provide a dose to the foetus, it is standard practice to use a lead apron as a shield. The reasons for not performing mammography as the first imaging modality are the younger age of most pregnant women, the low incidence of breast cancer at that age, and the increased density of the breast that is often produced by pregnancy. In selected circumstances, mammography can be quite helpful in the pregnant woman and when indicated should not be withheld because of the pregnancy.

### **Imaging the woman following treatment for breast cancer**

Women who have been treated for breast cancer are at an increased risk for the development of recurrent or a second primary breast malignancy. The primary role of imaging in this situation is the detection of clinically occult cancers. Follow-up

should be performed in conjunction with a clinical breast examination. The referring clinician should inform the radiologist of the nature of the previous malignancy and the treatment undertaken. The radiologist should have access to the imaging studies that detected the cancer and to any subsequent post-treatment studies. This is most important for women who have undergone breast conservation.

Mammography is the initial imaging modality, regardless of the woman's age. It is recommended that mammographic surveillance is initiated within the first six to 12 months post treatment and then annually.<sup>41</sup> Most recurrences and second primary malignancies occur within the first 10 years post treatment. As in screening, mammography has the potential for detecting clinically occult cancers with a higher likelihood of better prognostic features.

If mastectomy has been performed, standard MLO and CC images of the opposite breast are obtained. Additional images should be performed as necessary based upon the evaluation of the routine MLO and CC views. However, there is no evidence that the routine addition of extra images such as lateral or axillary views is helpful in this case.<sup>93</sup> Ultrasound may be used if considered necessary by the radiologist, based upon the mammographic findings.

Up to 40% of recurrences following breast conservation will be clinically occult and detected by mammography. If breast conservation has been performed, routine MLO and CC images of both breasts are obtained. Magnification spot views of the treatment site may be helpful for evaluation of calcifications in the area, but there is no evidence that routine use of these views is helpful. Additional images and ultrasound are used, as necessary, following evaluation of the standard images.<sup>94-96</sup>

For women who have undergone wide local excision for DCIS detected by calcification on mammography, post-operative mammography of the involved breast has been advocated to ensure complete removal of the calcification.<sup>98</sup> Routine annual post-treatment imaging is then performed.

Occasionally, scarring following breast conservation can be difficult to distinguish from recurrence. Image-guided non-excision core biopsy of the area can be used for differentiation in these cases. MRI has been reported to be useful in this situation.<sup>98</sup> Gadolinium-enhanced MRI is not considered helpful during the first six to 12 months following excision and radiation therapy, as there is an increase in false positives for up to one year. Sestamibi nuclear medicine imaging and contrast-enhanced colour Doppler ultrasound of the breast may also become useful modalities in differentiating recurrence from scarring after the first year. Sestamibi nuclear medicine imaging is discussed in Chapter 10.

If abnormalities are detected on the clinical breast examination, the imaging study should be tailored to answer the clinical question in the same manner as for symptomatic women who have not been treated for breast cancer. Imaging of the reconstructed breast or mastectomy site is not routine practice (see Chapter 2).

### **Imaging the woman with breast implants**

The symptomatic woman with breast augmentation prostheses may have symptoms related to the breasts and/or the implants. For women with symptoms such as breast lump, pain, or discharge, the evaluation would be similar to that of women without breast prostheses. Mammography should include implant exclusion (Eklund) views, in addition to the standard MLO and CC projections.<sup>85</sup> Compression spot views may also be necessary to image all of the breast tissue satisfactorily. When making an imaging appointment for a woman with implants, the radiology service should be made aware of the prostheses so they can allow additional time for mammography.

Image-guided non-excision biopsy can be performed in the presence of implants when required. Ultrasound is the preferred method of guidance as it allows visualisation of the needle throughout the entire procedure.

Ultrasound is useful in determining whether a palpable abnormality represents irregularity of the contour of the implant or extravasated silicone, rather than a primary breast mass. The role of mammography and ultrasound in evaluating



implant integrity is limited,<sup>99,100</sup> although both procedures can sometimes image extravasated silicone and thus document extracapsular rupture within the breast. Extracapsular rupture posterior to the prosthesis may be difficult to detect by either method.

Mammography and ultrasound have limitations in detecting intracapsular rupture. Abnormality of prosthesis contour is neither a specific nor a sensitive sign of intracapsular rupture. MRI is the breast imaging procedure of choice for the diagnosis of intracapsular rupture.<sup>101</sup> Sensitivities and specificities of up to 98% have been reported with MRI and the use of a dedicated breast coil.

### **Evaluation of incidental findings detected by imaging**

During the course of imaging, incidental findings may be detected on mammography or ultrasound. These findings may be indeterminate or suspicious for malignancy and require additional imaging tailored to the nature of the abnormality.

If calcification is detected, magnification spot views in a 90-degree lateral projection and CC position should be obtained. If the area of calcification is in dense breast tissue, ultrasound may be helpful in identifying associated abnormalities. If the abnormality is a mass, distortion or abnormal density, then the evaluation should proceed as for the evaluation of a woman with a mass lesion.

It is important to repeat the clinical breast examination to determine if the imaging abnormality can be detected on a targeted examination. It is also important for the radiologist to ensure that any impalpable lesion/s detected on ultrasound and mammography are adequately localised within the breast prior to non-excision or excision biopsy. If lesions are seen on both imaging modalities, the radiologist must determine whether the lesion seen on mammography is the same as that seen on ultrasound. Correlation is usually achieved, but may be difficult. Needle placement or dye injection and repeat mammographic images may be required for certainty.

## **Addressing the woman's needs during breast imaging**

The radiographer or sonographer is often the first, and possibly the only, health care professional with whom the woman has any significant contact during the imaging procedure. The radiographer/sonographer should be sensitive to the woman's feelings at all times, and specific training in this aspect of their role is recommended. The Centre has developed a *National Communication Skills Training Strategy*<sup>102</sup> for professionals working in breast oncology and associated disciplines. All staff, including reception staff, may benefit from communication skills training to satisfactorily address the concerns and information needs of women attending for breast imaging.

Although the vast majority of imaging test results are normal or benign, women undergoing imaging for further investigation of a breast symptom commonly experience increased levels of anxiety.<sup>17–22,71–77,103</sup> The woman is often tense and anxious when she attends the radiology service for imaging. An optimal image is more likely to be obtained if the radiographer/sonographer gains the woman's confidence and talks with her throughout the procedure so the woman can co-operate as required. Helpful communication strategies, particularly in reference to potentially threatening medical procedures are included in Appendix E.

### *Mammography*

The radiographer should demonstrate clearly to the woman how she is to be positioned for each mammographic view and explain that compression of the breast is essential if optimal films are to be obtained. Most women are able to tolerate adequate compression if it has been explained to them that it is an integral and essential part of obtaining a diagnostic mammogram, and that the compression will be released as soon as the X-ray has been taken.

The radiologist should be available at the time of the mammographic examination to check the initial mammograms, decide if they are technically adequate and assess whether the clinical problem has been resolved or if further views are required. It is desirable that the films are reviewed at the initial visit so

that any further views can be performed at that time, as recalling the woman for further views is likely to add considerably to her anxiety.<sup>103</sup>

### *Further views*

The woman should be informed of the reason for further imaging, such as technical repeats or the need for more detailed imaging of an area of clinical or radiological concern. The woman may require reassurance that the majority of further views demonstrate normal or benign appearances, and the radiologist should be available to discuss this with the woman if required. However, it is important that the woman is not given false reassurance if the initial views have indicated that she may have breast cancer.

### *Radiation exposure*

Some women are concerned about the hazards of radiation exposure. The radiographer should explain to the woman that modern mammography delivers a small dose of radiation to the breasts and that the benefits of the procedure are considered to greatly outweigh any theoretical risks of exposure to this amount of radiation.<sup>44</sup>

### *Ultrasound examinations*

Ultrasound examinations are generally well accepted by women, particularly as many women have had previous ultrasound examinations – for example, during pregnancy. It should be explained that ultrasound is not suitable as a screening procedure for breast cancer and that ultrasound is used to complement mammography. In addition, it should be explained that to maximise the effectiveness of the investigative process, the mammographic and ultrasound examinations must be correlated with each other and with the clinical findings.

## *Results of imaging*

The radiographer/sonographer should make it clear to the woman that s/he cannot give her the results of her imaging at the time of the examination, and that the radiologist will prepare a report. The service should ascertain the time and place of the woman's follow-up visit to her clinician to ensure that the report (and the films, if appropriate) have been received by that time. Before the woman leaves the radiology service she should be given the opportunity to raise any questions, clarify any issues or express any concerns.

## **Summary points**

- The selection of the most appropriate imaging procedure for the symptomatic woman depends on the age of the woman and the type of symptom.
- Mammography may be used in addition to ultrasound if:
  - The clinical or sonographic findings are suspicious or malignant
  - The ultrasound findings are indeterminate
  - The ultrasound findings are not consistent with the clinical findings
  - There is a strong family history of breast cancer.
- Ultrasound may be used in addition to mammography:
  - If there is a clinical abnormality and the mammogram is normal
  - If the mammogram findings are inconsistent with the clinical findings
  - If the mammogram findings are indeterminate, suspicious or malignant
  - To guide a needle or core biopsy.

## CHAPTER 6      REPORTING BREAST IMAGING

### Standardised reporting

Synoptic and standardised reporting systems have been introduced in radiology and other disciplines with the aim of standardising the information contained in reports and improving communication among clinicians and other health care professionals. The term ‘synoptic reporting’ generally describes reporting systems that contain a summary of the essential information presented in a checklist format to ensure that no important information is omitted. ‘Standardised reporting’ is based on the use of a standard language and descriptions with an agreed classification system, and may include synoptic reporting. In the clinical literature however the terms ‘synoptic’, ‘standard’ and ‘standardised’ are frequently used interchangeably.

Research indicates that synoptic reporting and, more specifically, the use of checklists, are the most effective methods of improving the content and completeness of reports<sup>48-51</sup> and have the potential to improve care for women.<sup>48</sup> In pathology, standardised reporting has been demonstrated to be useful when it is used as a reminder of essential items to be included in a report, in conjunction with narrative reporting.<sup>104-106</sup> In radiology, the Breast Imaging Reporting and Data System (BIRADS)<sup>107</sup> used in the United States has improved the completeness of reports by identifying essential items to be included in reports and by specifying the manner in which these items are described. Standardised reporting may also reduce the risk of misinformation,<sup>51</sup> improve clinician satisfaction,<sup>49</sup> adapt to new technologies and increase the ability to compare research or develop guidelines.<sup>81</sup>

Synoptic reports have been thought to reduce the variability found in the description and interpretation of breast imaging.<sup>108</sup> Although synoptic reporting can encourage the inclusion of all essential items in a report, it cannot correct variations in the way that different observers apply terminology. For instance, considerable variability in the use of terminology has been identified among BIRADS users, despite publication of a lexicon.<sup>109,110</sup>

The use of a standardised reporting system for breast imaging is a way of improving communication between the radiologist and referring clinician. Existing reporting systems such as BIRADS are not applicable to the Australian setting. A new standardised reporting system suitable for the Australian setting is therefore proposed. The proposed standardised reporting system has been adapted to the Australian context and its development is supported by the RANZCR Breast Imaging Reference Group. The proposed standardised reporting system aims to improve communication by increasing the number of reports containing all essential descriptors of lesions, correlating imaging findings with clinical findings, providing an imaging diagnosis and utilising a classification system based on clinical management. The minimum data to be included in a breast imaging report and a sample report are provided in Appendix G.

The standardised reporting system provided in Appendix G is envisaged as a checklist to be added to a narrative report. Alternatively, lesions could be described in the imaging characteristics sections and the standardised format could be used as a stand-alone report. The proposed standardised report is lesion-based, tracking individual lesions and considering mammography and ultrasound characteristics for each lesion in the same section, rather than reporting the imaging findings separately. Importantly, the standardised report requires the radiologist to offer one classification finding per lesion. The diagnosis and classification codes are likely to reduce ambiguity in reports and may also be used by individual radiologists for audit purposes. The classification system for use with the proposed standard report is discussed further in this chapter.

### **Level of significance of radiological findings – a classification system**

A standardised, management-based classification system for imaging findings would potentially prevent interpretation errors and improve the management of women with breast symptoms.

The use of a standardised classification system encourages decision-orientated reporting<sup>112</sup> and can clearly convey the importance of clinical and radiological findings to referring clinicians.<sup>112</sup> A common classification system could be

incorporated into future diagnostic computer programs<sup>113</sup> and has the potential to assist in self-audit or broader evaluations assessing cancer detection rates.<sup>114</sup>

It is recommended that the following breast imaging classification system be used as part of the proposed standardised report shown in Appendix G. For each lesion identified, the anatomical position should be specified and a classification assigned. This classification system is consistent with the approach used by Australian pathologists,<sup>45</sup> and is similar to published breast imaging scoring or classification systems used in other countries.<sup>107,115–118</sup>

The classification system may also be used by radiological practices to provide radiologists with feedback for improvement. A database using the 1–5 classification system can be developed that allows information such as positive predictive values to be calculated for self-audit.<sup>114</sup>

**It is recommended that the classification is applied to all reported lesions. Levels of suspicion range from 1 to 5, as follows:**

1. No significant abnormality

- There is no significant imaging abnormality
- Standard-format checklist is not required
- If there is a clinical symptom and there are no imaging abnormalities to explain it this should be stated in the report
- This classification does not preclude biopsy of any clinically suspicious area.

2. Benign findings

- No further imaging is required
- Standard-format checklist is optional
- Correlation of findings with clinical symptoms, if present, should be stated in the report
- This classification does not preclude biopsy of any clinically suspicious area.

### 3. Indeterminate/equivocal findings

- Requires further investigation, usually FNA cytology/core biopsy
- Management should be based on the outcome of the triple test
- There may be a limited role for early follow-up (eg inflammation)
- Further investigation will almost always resolve the indeterminate nature of the lesion
- Correlation of findings with clinical symptoms, if present, should be stated in the report
- This classification does not preclude biopsy of any clinically suspicious area.

### 4. Suspicious findings of malignancy

- Requires further investigation
- May require excisional biopsy
- Correlation of findings with clinical symptoms, if present, should be stated in the report.

### 5. Malignant findings

- Requires further investigation, even if non-excision (percutaneous) sampling is benign
- Correlation of findings with clinical symptoms, if present, should be stated in the report.

When reporting the classification, both the number and the description of the classification should be stated. For example ‘Category 2. Benign findings’ or ‘Category 3. Indeterminate/equivocal findings’.

## **Clinical perspectives of a good imaging report**

All referring clinicians require the radiology report to describe the imaging features of the breast/s clearly and unambiguously, particularly in the area of clinical interest. The radiologist’s ability to provide such information will depend, in part, on the quality of the information supplied by the referring clinician in the request form (see Chapter 3).



The radiologist need not tailor the report to the discipline of the referring clinician. It is the responsibility of the referring clinician to ensure that s/he has a clear understanding of the radiology report. In some instances this may necessitate contacting the radiologist for further clarification or information.

A good imaging report is a stand-alone document. Although clinicians gain useful information from seeing the printed images of mammogram or ultrasound films, this is not always possible and they rely heavily on the information contained in the report. The report should therefore contain enough information to assist the clinician in the absence of the films, and must include sufficient detail to permit comparison with past or future reports if necessary.

Each radiology practice should provide reports as promptly as possible, though the feasible reporting interval will vary between practices. 'Urgent' cases should be so labelled on the request form, or the radiologist should be informed by telephone. The referring clinician should indicate the preferred means of receiving urgent reports and provide relevant contact details, such as telephone/facsimile numbers or an email address.

Clinical perspectives of what constitutes a 'good' report may vary, depending on the type of information most relevant to the practice of each individual clinician. However, there are a number of generic features of a good report to be considered in diagnosis, treatment and follow-up.

### *Making a diagnosis*

From the referring clinician's point of view, a good report:

- *Contains a concise description of the radiographic and/or sonographic appearances in sufficient detail to facilitate the clinician's interpretation of the images, and allows comparisons with past and future reports.*<sup>120</sup> The report should avoid lengthy and complex sentences as these can compromise the clarity of the language.<sup>121</sup> However, the detail in the report should provide enough information to help the referring clinician make a management decision.

Some examples of useful expressions are as follows:

- 'The most likely diagnosis is radial scar but this could only be confirmed histologically'
- 'If biopsy of this area is to be performed this would be best done by stereotactic biopsy'.

Ambiguous or equivocal statements should be avoided' for example:

- 'Recommend biopsy if clinical suspicion persist'
- 'Cannot rule out malignancy'
- 'No abnormality seen but a surgical opinion may be of value'.

• *Records the size and location of abnormalities within the breast.* This is particularly important when an area with suspicious or malignant features is described, and should include:

- The number and radiological appearances of each lesion and any other abnormalities such as skin thickening, calcifications etc
- The location of the tumour, indicating the side of the breast, anatomical and/or clock-face position and distance from the nipple.

The report should also include comments about the correlation of radiological and/or sonographic findings with clinical breast examinations. In addition, it includes comments about which imaging modality best demonstrated the abnormality or abnormalities. For example, a clinically symptomatic cyst may not have been seen on mammography but was clearly identified on ultrasound.

The report could also suggest other imaging modalities that may add further information if required.<sup>119</sup> However, it is the referring clinician's responsibility to consider the role of further investigation and the report should not commit the woman to further imaging unless this is clinically indicated.

• *Expresses an opinion as to the diagnosis.*<sup>119</sup> This could be weighted with a level of significance, if required. Alternatively, a differential diagnosis could be given, with relative probabilities of each.<sup>119</sup> The referring clinician should then weigh up this information with information from other test results for each

individual case. The report should not advocate short-term follow-up of abnormal findings: if an abnormality is seen, the report should simply indicate that it is benign, indeterminate or suspicious of malignancy (refer to classification system discussed earlier).

- *Answers the clinical question.*<sup>119</sup> This will depend on the quality of information recorded by the referring clinician on the request form, and will reflect the level of communication with the radiologist. The report should also include specific comments where specific questions are asked.<sup>121</sup>

### *Response to treatment*

For women who have been undergoing initial systemic therapy, or pre-operative radiotherapy in order to reduce the size of a primary cancer, a good report will also: Compare current breast imaging to imaging prior to systemic therapy  
Comment on any changes evident – for example, reduction in the size of the cancer.

### *Follow-up*

The referring clinician should remind the woman to take along all previous breast imaging films when she attends for follow-up imaging. For women undergoing imaging after breast cancer treatment, a good report will:

- Compare current imaging to original (pre-treatment) imaging and relevant interval imaging
- Comment on any new abnormalities in either breast
- Suggest any imaging modalities that may provide further information
- Avoid statements that commit a clinician to investigate by biopsy, as this may not be appropriate when imaging is correlated with the history and clinical breast examination of the woman
- Comment on the primary tumour bed of the conserved breast.

### **Summary point**

- Synoptic and standardised reporting systems have been introduced in radiology and other disciplines with the aim of standardising the information contained in reports and improving communication among clinicians and other health care professionals.

## CHAPTER 7      **COMMUNICATING RESULTS TO THE WOMAN**

Only once the referring clinician has available the results of all necessary tests – clinical breast examination, imaging with or without pathology – can these results be collated to either confirm a diagnosis or indicate the need for further tests. Therefore, a result only, but not a diagnosis, can be communicated immediately after imaging.

If the woman asks the radiographer/sonographer performing the test about the results and their meaning, s/he should advise the woman that s/he is not qualified to discuss the findings and that results should be discussed in full with her referring clinician. The radiographer/sonographer can inform the woman how she will receive her results, and give an approximate time for when the results will be made available.<sup>8,122</sup>

In some circumstances it may be appropriate for the radiologist to provide the woman with some information about the findings during the procedure. Each radiology facility should establish and implement a system to ensure that imaging results suggesting a malignancy are communicated immediately to the referring clinician. Providing a system for the communication of urgent reports is an accreditation standard of the Royal Australian and New Zealand College of Radiologists.

The managing clinician should make every effort to provide results to the woman as soon as possible to help minimise her anxiety.<sup>18,21,73</sup> It is preferable that results are given in person, and in the majority of cases this will be done by the referring clinician. In cases of geographical or physical difficulties, or in selected cases where results are benign, the results may be given over the telephone after prior arrangement with the woman. The vast majority of women will be informed they have a benign outcome, but may still have questions relating to the area of interest, continuity of care and need for follow-up. For example, if the diagnosis is fibroadenoma, the woman may have questions about the significance of the condition, the options for management and whether it may develop into cancer.

The way in which clinical information is presented to the woman can affect her decision about further investigations and/or treatment, with information presented positively more likely to be taken up.<sup>123,124</sup> Individual preferences will determine how women prefer probabilities presented to them, either as numerical and/or descriptive estimates of risk.<sup>125</sup> In addition, the use of the term ‘risk’ can have different meanings for the woman and the clinician. Consequently, when discussing the outcomes of tests a clinician needs to check the woman’s understanding of numerical or descriptive estimates to ensure she has correctly interpreted the information.<sup>78</sup>

The referring clinician may choose to use the breast imaging film and the radiologist’s report to explain the meaning of the results to the woman. For reports using the classification system proposed in Chapter 6, an explanation of the classification would be beneficial. For example, if the classification ascribed to a lesion is ‘3. Indeterminate/equivocal lesion’, it should be explained to the woman that this will require further evaluation, with management based upon the results of the triple test.

The woman commonly retains a copy of the breast imaging film/s. The referring clinician should also offer her a copy of the radiologist’s report. Some research indicates that patient-held records are beneficial for the patient and have considerable medico-legal benefit, such as documentation of doctor-patient communication. A written record can also help the woman remember her results and can improve her satisfaction with her care.<sup>126</sup>

Managing clinicians may benefit from setting up reminder systems to indicate when results are due, whether they have been received and whether they have been communicated to the woman. This communication will involve providing the results in person or (where appropriate) by phone, and ensuring that the woman has been offered a written copy of her results.<sup>127,128</sup>

A final diagnosis can be communicated only after the referring clinician has collated and reviewed the results from all the tests conducted, and determined

that they are consistent. When discussing a diagnosis with the woman, particularly if a breast cancer is suspected, there are a number of recommendations to assist this process. Recommendations for telling a woman she has breast cancer, a recurrence or metastasis are provided in *Psychosocial clinical practice guidelines: providing information, support and counselling for women with breast cancer* and are summarised in Appendix E.

### **Summary point**

- A final diagnosis can only be communicated once the referring clinician has collated and correlated the results from all the tests conducted and determined that they are consistent.

## CHAPTER 8      QUALITY IMPROVEMENT

Quality improvement focuses on a continuous process of improvement rather than on simply finding and correcting problems. At the level of individual radiology practices both external and internal audit processes are required to ensure the quality of the service is improved and maintained. Quality improvement needs to be continuous and evaluated regularly.

### **External audit**

Relevant training bodies define many external audit processes, which address professional standards for medical and non-medical staff as well as technical standards for mammography and ultrasound equipment. For example, the RANZCR has established a mammography standards program that sets out criteria for personnel qualifications, imaging quality, dose, equipment safety and labelling.<sup>3,129</sup>

Within the BreastScreen Australia Program, standards have been set for quality control of mammography and other equipment.<sup>2</sup> A series of performance indicators has also been established for the BreastScreen Australia Program, including overall cancer detection rate, small cancer detection rate and interval cancer detection rate. These measures are influenced by a combination of technical factors (film quality, equipment specification),<sup>130</sup> personnel factors (skill and knowledge of technical and medical staff) and epidemiological factors in the screened population. Regular audits of individual BreastScreen Services against the performance indicators will provide information about performance and identify areas requiring more focused improvement.

### **Internal audit**

Internal auditing practices are less well established. An ongoing commitment to continuous quality improvement within all radiology practices is highly desirable. Such audits may focus on workplace issues such as general efficiency and report turnaround time, professional issues such as report quality or training and education requirements, and other issues such as customer satisfaction. It should be recognised

that there are two ‘customers’ for every case within a radiological practice – the woman and the referring clinician. Provision of a timely, accurate and clear report will enhance clinician satisfaction and consequently patient satisfaction. Ensuring that the woman undergoes her breast imaging in a supportive environment will also improve her satisfaction (see Chapters 4, 5 and 7).

Two overseas studies reviewed intra-departmental radiology practices to identify ways of improving general workplace efficiency.<sup>131,132</sup> Both studies concluded that the key elements of an efficient workplace are good communication between staff at all levels, and identifying and removing organisational obstacles to the work.<sup>131,132</sup>

Other overseas studies have examined factors affecting the time taken to produce a radiology report.<sup>117,133–139</sup> These studies found that simple, mainly organisational, interventions achieved significant streamlining of services. Four of these studies<sup>117,133,137,139</sup> showed that computerised, form-driven reporting could reduce turnaround time, with one study estimating that 80% of mammographic examinations were suitable for standardised reporting.<sup>117</sup>

The accuracy of reports is difficult to assess, they are based on personal interpretation of visual images and are inherently subjective.<sup>114</sup> Substantial variation between different radiologists’ interpretations of the same mammographic images has been reported.<sup>140</sup> Techniques to standardise reporting, such as the use of templates and checklists in the form of synoptic reports, should help to ensure that critical information is included with the report.<sup>111,112</sup> Standardised reporting is discussed in further detail in Chapter 6.

Several radiology practices in the United States have assessed the clarity and readability of their reports by surveying the clinicians who receive them.<sup>120,121</sup> Each service was able to improve the quality of its reports as a result of the feedback obtained.<sup>120,121</sup>



The quality of a radiological report partly depends on the quality of the request. Two studies have examined the information included on request forms and found variation in ordering behaviour between clinicians.<sup>142,143</sup> Commonly identified problems included a lack of clinical information, the ordering of inappropriate tests, unreasonable demands for urgency and poor legibility. These studies postulated that establishing a mechanism for improved dialogue between the requesting clinician and radiologist would improve the quality of requests.<sup>142,143</sup>

Training and continuing education should be part of a continuous quality improvement program. However, qualifications alone do not guarantee proficiency in the practice of breast imaging, and theoretical knowledge is not necessarily reinforced through practice. Within each individual radiology service, regular auditing and reviews of results should be conducted so that additional training and continuing education requirements can be identified. Chapter 9 discusses training and continuing education opportunities.

### **Summary point**

- Both external and internal audit processes are required at the level of individual radiology practices to ensure the quality of the service is improved and maintained.

## CHAPTER 9      TRAINING AND CONTINUING EDUCATION

Breast imaging requires a high level of operator skill and equipment quality control to produce high-quality images within safety standards; and skill and experience in reading and interpreting imaging films are required to obtain an accurate report and diagnosis. Training and continuing education are key strategies for ensuring and maintaining a high standard of imaging services, and should be part of a continuous quality improvement program. In particular training in communication skills should be encouraged as part of a continuous quality improvement program because effective communication between clinicians and their patients has been shown to improve patient understanding,<sup>144</sup> satisfaction<sup>145</sup> and health care outcomes.<sup>146</sup>

Professional colleges generally specify their training and continuing education requirements for accreditation. The Quality and Accreditation Program of the RANZCR requires that radiologists reporting on mammography view a minimum of 480 mammograms each year and document 15 hours of continuing professional development in mammography every three years.<sup>147</sup> Equivalent governing bodies in the United Kingdom<sup>12</sup> and the United States<sup>148,149</sup> also specify continuing education accreditation requirements for breast imaging.

The Australian Institute of Radiography (AIR) is the local professional association representing medical radiation science professionals including radiographers, medical imaging practitioners, radiation therapists and sonographers. The AIR sets standards and accredits courses in mammography for radiographers. Radiographers who complete an AIR-accredited training program are eligible to apply for an AIR Certificate of Clinical Proficiency in Mammography (CCPM). To renew the certificate, radiographers must satisfy the AIR requirements for continuing education and clinical practice.

The Australasian Sonographer Accreditation Register (ASAR) accredits sonography training and education programs and maintains a register of accredited sonographers. Sonographers must meet continuing professional development requirements in order to remain on the ASAR register.

## Opportunities within Australia

A list of useful contacts for training in Australia is included in Appendix H. The RANZCR strongly promotes and encourages continuing education, and its Continuing Professional Development Committee has produced a manual outlining eligible continuing professional development activities and how member radiologists can attain the recommended 180 continuing professional development credit points in a three-year period.<sup>147</sup> One credit point of continuing professional development is the equivalent of approximately one hour of medical professional development. Examples of continuing professional development activities to accumulate points include viewing RANZCR educational videos, authoring journal articles and attending scientific meetings.

The RANZCR also conducts courses in breast imaging across Australia and provides opportunity for professional development at its annual scientific meetings, through the journal *Australasian Radiology*, through policy guidelines issued by the BIRG, and through advanced training positions for registrars. In addition, the RANZCR's Breast Interest Group conducts biennial meetings to address current breast imaging issues through workshops and presentations by local and international speakers.

The Australasian Society for Ultrasound in Medicine is a multidisciplinary group whose primary roles are to facilitate the dissemination of scientific information, to provide continuing education and to set standards of practice in the specialty of ultrasound in medicine. The Australian Society for Ultrasound in Medicine offers two ultrasound diplomas awarded after written, oral and practical examinations and the fulfilment of prescribed practical experience. These examinations are available to candidates resident in Australia or New Zealand who have appropriate prerequisite qualifications. Sonographers with the appropriate prerequisite educational qualifications (including radiography, nursing, or medical imaging technology) and at least two years practical experience in medical ultrasonography are eligible for the Diploma of Medical Ultrasonography. The Diploma of Diagnostic Ultrasound is available to appropriately qualified medical graduates who hold a specialist degree and have been practising in diagnostic ultrasound for

at least two years. The Australian Society for Ultrasound in Medicine also publishes a quarterly bulletin that includes case reports, an education section, and feature articles. The Society also conducts lectures and offers educational resources, including videotapes of lectures given at its meetings. There are no formal educational requirements for membership.

State and Territory branches of the AIR, and some educational institutions, offer short courses for medical radiation science professionals on a variety of topics. Branches of the AIR also conduct regular seminars. The AIR issues a Certificate of Professional Development Compliance to members participating in the program who accumulate 24 credit points within a 24-month period. One credit point is equivalent to one contact hour of professional development.<sup>150</sup> A wide range of activities is recognised for continuing professional development, including paper presentations, conference attendance and university lecture preparation and delivery. Continuing education is mandatory for renewal of the AIR's Certificate of Clinical Proficiency in Mammography and is strongly recommended to AIR members, but is not mandatory for AIR membership.<sup>150</sup>

The Australasian Society for Breast Disease is a multidisciplinary society that aims to bring together all those interested in the prevention, diagnosis, treatment and research aspects of breast disease. The Society provides regular scientific meetings with a multidisciplinary content.

The International Breast Ultrasound School, which provides educational programs throughout the world, holds seminars in Australia.

Individual tuition can also be arranged with many specialist breast clinics or BreastScreen Australia screening and assessment services.

The National Breast Cancer Centre has developed a *National Communication Skills Training Strategy*<sup>102</sup> for professionals working in breast oncology and associated disciplines. This strategy supports the implementation of the *Psychosocial clinical practice guidelines: providing information, support and*

*counselling for women with breast cancer*<sup>78</sup> and aims to ensure that an opportunity to participate in communication skills training is provided to all interested clinicians, general practitioners and other health professionals.

Continuing education may also be accessed via the Internet.<sup>151,152</sup> Interactive continuing education activities via the Internet may become an innovative training method in the future, especially for clinicians in rural and remote areas of Australia.

### **International opportunities**

Attending international seminars, workshops and conferences is another option for Australian imaging professionals seeking to update their skills and knowledge. International bodies that conduct courses open to non-members include the International Breast Ultrasound School, the European Federation of Societies for Ultrasound Medicine and Biology, the Royal College of Radiology (United Kingdom), the Society of Breast Imaging (United States), the American College of Radiology and Mammography Education Inc. Their website addresses are listed Appendix H.

### **Summary point**

- Training and continuing education are key strategies for ensuring and maintaining a high standard of imaging services and should be part of a continuous quality improvement program.

## CHAPTER 10 OTHER IMAGING MODALITIES

While mammography and ultrasound remain the mainstay imaging modalities for screening and assessing breast lesions, other imaging tools may also be useful. This chapter outlines other possible imaging modalities, which are presented in two groups: (i) those commercially available, although not necessarily widely, and (ii) emerging technologies. It should be noted that additional imaging modalities exist which are not listed here.

The imaging modalities described here are essentially all functional imaging modalities and include MRI, positron emission tomography (PET), scintimammography and thermography. The emerging technologies of particular interest are digital mammography and computer-aided diagnosis.<sup>153</sup> None of these imaging modalities should be used or interpreted in isolation, and their results should always be correlated with the results of the conventional tests.

The current rapid expansion of new technologies for the detection and diagnosis of breast lesions has led to inappropriate promotion by the news media of new technologies that are often untested and unproven. Such inaccurate information has the potential to be detrimental to patients. New technologies should be rigorously evaluated and introduced in a planned and appropriate manner.<sup>154</sup> Information about available imaging tools and emerging imaging technology can be obtained by participating in the continuing education activities of the various professional colleges and organisations in Australia and overseas. The Centre also provides an ongoing update of new technologies in breast cancer diagnosis, which can be accessed via the Centre's website at [www.nbcc.org.au](http://www.nbcc.org.au)

### **Commercially available imaging modalities**

#### *Magnetic resonance imaging*

Magnetic resonance imaging (MRI) uses electromagnetic waves to oscillate the nuclei of hydrogen atoms in the body. The strength and location of the signals produced by these oscillations is used to generate images of the breast. MRI is a costly technology and is not readily available in Australia. It is a complementary imaging modality, providing additional information only. MRI can be useful in

difficult diagnostic situations where conventional imaging has been unhelpful and there is high index of clinical suspicion.<sup>155</sup> Currently, large trials are still needed to evaluate the utility of MRI, such as the trial conducted by the National Cancer Institute in the United States.<sup>153,156</sup>

In women with breast symptoms, MRI has been reported to have a sensitivity ranging from 93% to 99% and a specificity ranging from 89% to 99%.<sup>157–159</sup> However, the specificity of MRI remains an ongoing area of investigation.<sup>153,160</sup> There is a significant false positive/false negative rate depending upon the technical sequence employed.

The major indications for MRI include the evaluation of the integrity of augmentation implants and the differentiation between fibrosis and tumour recurrence following breast-conserving treatment for cancer.<sup>153,160–162</sup> Other possible indications for MRI include searching for the primary tumour when lymph node metastases have been detected and clinical breast examination, mammography and ultrasound are negative; determining the extent of breast cancer; and screening of high-risk women.<sup>153,160</sup>

### *Positron emission tomography*

Positron emission tomography (PET) using 18-FDG (fluorodeoxyglucose) or labelled oestrogen with tumour-avid tracers has been used. However, PET should still be regarded as a research tool. PET is expensive and not widely available, but may be useful to detect primary cancers, nodes and metastatic disease, and to monitor response to treatment.<sup>163,164</sup>

### *Scintimammography (or breast scintigraphy using Tc<sup>99m</sup> sestamibi)*

Scintimammography is a nuclear medicine imaging procedure that uses Technetium (Tc) 99m sestamibi as the tracer. Functional images of the breast and breast cancers may be obtained. This is a complementary imaging modality with limited use. Its indications may include women with dense breast tissue, augmentation implants, severe dysplasia or architectural distortions secondary to surgery/radiotherapy and selected cases of women at high risk of breast cancer.<sup>24,165–167</sup>

## *Thermography*

Breast thermography, also known as thermal breast imaging, is a technique that produces ‘heat pictures’ of the breast. The rationale for thermography in breast imaging is that the skin overlying a malignant breast lesion can be warmer than that of surrounding areas.

Fewer than 50% of breast cancers detected by mammography screening would have an abnormal thermogram.<sup>168</sup> Thermography remains of research interest only. Neither the RANZCR nor BreastScreen Australia<sup>169</sup> currently recommend its use.

## **Emerging technologies**

### *Digital mammography*

Digital mammography uses traditional X-ray generators and tubes to produce an X-ray beam. This X-ray beam is converted into digital information that can be stored electronically, transmitted, displayed, analysed and manipulated in a number of ways.

The ability to separate acquisition and display of the image allows computer-aided diagnosis and data retrieval and electronic data transmission. This may facilitate remote screening and allow digital subtraction mammography, three-dimensional reconstructions and dual subtraction mammography.

Recent studies indicate that digital mammography is equivalent to film screen mammography. The National Cancer Institute in the United States is currently conducting trials to address the value of this emerging technology.<sup>156</sup>

## **Summary points**

- The imaging modalities such as MRI, PET and Scintimammography should be regarded as complementary to the standard imaging by mammography and ultrasound and should only be considered in selected situations.
- The role of some commercially available and emerging technologies continues to be defined.



## **APPENDIX A      PROJECT TEAM MEMBERS**

Dr Roslyn Adamson	Radiologist
Dr Verity Ahern	Radiation Oncologist
Clinical Associate Professor Michael Bilous	Pathologist
Mr Pat Cregan	Surgeon
Ms Claire Davey	Project Officer, Early Detection, National Breast Cancer Centre (February 2000 – February 2001)
Ms Elizabeth Develin	Project Officer, Early Detection, National Breast Cancer Centre (March 2001 – April 2002)
Dr Andrew Field	Pathologist
Dr Lyn Kemp	Project Officer, Early Detection, National Breast Cancer Centre (October 1999 – February 2000)
Dr Marjorie Kossoff	Radiologist
Ms Andriana Koukari	BreastScreen Australia
Dr Jenny Masters	General Practitioner
Ms Caroline Nehill	Project Co-ordinator, Early Detection National Breast Cancer Centre (April 2002 onwards)
Dr Mary Rickard	Radiologist
Ms Margaret Tassell	Consumer Representative, Breast Cancer Network of Australia
Mr Bruce Tulloh	Surgeon
Ms Fleur Webster	Manager, Early Detection, National Breast Cancer Centre (to November 2001)
Dr Helen Zorbas	Breast Physician and Clinical Director, National Breast Cancer Centre

## APPENDIX B      DIAGNOSTIC IMAGING OPTIONS

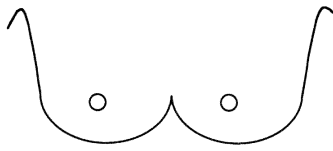
The following information is from *The investigation of a new breast symptom: a guide for general practitioners*.<sup>25</sup>

### Notes on diagnostic imaging options

For investigation of a new breast symptom: GPs providing a **detailed history** will assist the radiologist to perform **appropriate targeted imaging**.

Under age 25	Under age 35	Over age 35
<p><b>Ultrasound is recommended as the first imaging modality</b></p> <p><b>Mammography is only justified</b> if the clinical or sonographic findings are suspicious or malignant.</p>	<p><b>Ultrasound is recommended as the first imaging modality</b></p> <p><b>Mammography is an acceptable initial investigation</b> if:</p> <ul style="list-style-type: none"> <li>• the woman is in the upper range of this age group.</li> </ul>	<p><b>Mammography is recommended as the first imaging modality</b></p> <p><b>Ultrasound is an acceptable initial investigation</b> if:</p> <ul style="list-style-type: none"> <li>• the lump is clinically consistent with a simple cyst, and there is a history of cysts and a normal (non-cancerous) mammogram in the last year. (In this case, if ultrasound is not readily available, eg in isolated regions, then aspiration may be performed without imaging.)</li> </ul>
<p><b>In pregnancy or lactation</b></p>	<p><b>Mammography may be used in addition to ultrasound</b> if:</p>	
<p><b>Ultrasound is the most useful modality</b></p> <p><b>Mammography should be used</b> if the clinical or sonographic findings are suspicious or malignant.</p>	<p><b>Mammography may be used in addition to ultrasound</b> if:</p> <ul style="list-style-type: none"> <li>• the clinical or sonographic findings are suspicious or malignant <i>or</i></li> <li>• the ultrasound findings are indeterminate <i>or</i></li> <li>• the ultrasound findings are not consistent with the clinical findings</li> <li>• there is a strong family history of breast cancer.</li> </ul>	<p><b>Ultrasound may be used in addition to mammography:</b></p> <ul style="list-style-type: none"> <li>• if there is a clinical abnormality and the mammogram is normal <i>or</i></li> <li>• if the mammogram is inconsistent with the clinical finding <i>or</i></li> <li>• to guide a needle or core biopsy.</li> </ul>
<p><b>Mammography should be performed in all age groups if the clinical or sonographic findings are suspicious or malignant.</b></p>		

## APPENDIX C EXAMPLE OF A REQUEST FORM FOR BREAST IMAGING

<b>Patient details</b>	
Name of patient: _____ D.O.B : ___ / ___ / ___ Hospital ID: _____	
Address: _____ Phone: _____	
<b>Relevant History:</b> _____ _____	
<b>Clinical Notes:</b> _____ _____	
Differential Diagnosis: _____ _____	
<b>Examinations requested</b>	
Bilateral mammography <input type="checkbox"/>	Bilateral mammography and ultrasound <input type="checkbox"/>
Ultrasound <input type="checkbox"/>	Non-excision biopsy <input type="checkbox"/>
<b>Any other specific request:</b> _____ _____	
<b>Results:</b>	
Urgent <input type="checkbox"/>	Routine <input type="checkbox"/>
Films and report with patient <input type="checkbox"/>	
Fax report <input type="checkbox"/>	Phone report <input type="checkbox"/>
Deliver films and report <input type="checkbox"/>	
If urgent, relay report by: mobile phone: _____ Fax: _____	
<b>Referring doctor:</b>	
Name: _____ Provider No: _____	
Address: _____ Date: ___ / ___ / ___	
Phone: _____ Fax: _____	
Signature: _____	
<b>Copies to:</b> _____	
(if other than above) _____	

**PLEASE BRING ANY PREVIOUS FILMS**

**Radiology service locations**

Address: \_\_\_\_\_ Phone: \_\_\_\_\_

Address: \_\_\_\_\_ Phone: \_\_\_\_\_

Address: \_\_\_\_\_ Phone: \_\_\_\_\_

**Radiology service details**

Name: \_\_\_\_\_

Address: \_\_\_\_\_ Phone: \_\_\_\_\_

Opening hours: \_\_\_\_\_ Days: \_\_\_\_\_

**Location Details**

Include map

*Space for map*

**Transport Details**

Bus route: \_\_\_\_\_

Train/bus timetable: \_\_\_\_\_

Car park facilities: \_\_\_\_\_

## APPENDIX D A TOOL FOR ASSESSING WHETHER A WOMAN IS AT INCREASED RISK OF DEVELOPING BREAST CANCER DUE TO FAMILY HISTORY



You can find out if you may have an increased risk of developing breast cancer by completing the tick-box questions below. You will be in either **Category 1 (Population Risk)** or in **Category 2/3 (Moderately Increased Risk/Potentially High Risk)**. These categories are described on the following page.

### **Instructions:**

- Please tell us about your blood relatives, your mother, sisters and daughters, and your grandmothers, aunts and nieces on both your mother's and your father's sides of the family.
- Please tick the answers below that are most appropriate to your family.
- If you are unsure of the answer, please tick **NO** or **DON'T KNOW**.

### **1. Have any of these blood relatives – your mother, sisters, daughters, grandmothers, aunts and nieces – ever had breast cancer?**

- Yes  Go to question 2.  
No or don't know  Go to Category 1 on the next page and **DO NOT** answer any more questions.

### **2. Have any of your mother, sisters or daughters – ever had breast cancer?**

- Yes  Go to question 3.  
No or don't know  Go to question 5 and **DO NOT** answer questions 3 or 4.

### **3. Were any of the women in question 2 diagnosed with breast cancer before the age of 50?**

- Yes before 50  Go to Category 2/3 on the next the page and **DO NOT** answer any more questions.  
No or don't know  Go to question 4.

### **4. How many women in question 2 have had breast cancer?**

- One only  Go to question 5.  
Two or more  Go to Category 2/3 over the page and **DO NOT** answer any more questions.

### **5. Have any of these blood relatives – your grandmothers, aunts or nieces, on either your mother's or your father's sides of the family – ever had breast cancer?**

- Yes  Go to question 6.  
No or don't know  Go to Category 1 over the page and **DO NOT** answer any more questions.

**6. Please tick ONE of the following statements that describes your blood relatives – your mother, sisters, grandmothers, aunts and nieces – who have ever had breast cancer:**

I have one blood relative who has had breast cancer

Go to Category 1 over the page.

I have one blood relative on each side of my family who have had breast cancer

Go to Category 1 over the page.

I have two or more blood relatives on my mother's side who have had breast cancer

(Note: daughters and sisters can be counted on either side of the family.)

Go to Category 2/3 over the page.

I have two or more blood relatives on my father's side who have had breast cancer

(Note: daughters and sisters can be counted on either side of the family.)

Go to Category 2/3 over the page.

**This questionnaire was developed and trialed in collaboration with BreastScreen Australia**

## **DO YOU HAVE BREAST CANCER IN YOUR FAMILY?**

**This information sheet is to help you work out if you have an increased chance of developing breast cancer and if so what you can do. The information is based on what we know through research.**

### **Most breast cancer is not inherited**

Breast cancer is a common disease: about 1 in 11 women in Australia will develop breast cancer by age 75. As a result, many women have a relative with breast cancer – simply by chance. Some women have a strong family history of breast cancer, for example several close blood relatives on the same side of the family who have the disease. These women may have inherited a fault in a gene which may eventually lead to the development of breast cancer. However, this is uncommon and less than 5% of all breast cancers are caused by an inherited gene fault. And although a woman who inherits a gene fault does have an increased chance of developing breast cancer, she may never develop the disease.

### **Your family history becomes more important in increasing your risk of breast cancer:**

- The more blood relatives you have on the same side of the family who have had breast cancer
- The younger these relatives were when they were first diagnosed
- The more closely related these relatives are to you.

### **How do I find out if I may have an increased risk of developing breast cancer?**

You may like to complete the tick-box questions on the previous page. Based on your family history, you will be in one of these three categories:

#### **Category 1 – Population Risk**

If the current history of breast cancer in your close relatives puts you in this category, or if you have no relatives with breast cancer, your risk of breast cancer is about the same as that of the great majority of women in the general population. At the present time, you do not need to do anything more than any other woman in the population. Like all women, you are advised to:

- See your general practitioner without undue delay about any breast changes which are not normal for you
- Ask your general practitioner about how often you should have your breasts examined
- If you are over 50, ring 13 20 50 for a free screening mammogram with BreastScreen every two years.

## **Category 2 – Moderately Increased Risk or Category 3 – Potentially High Risk**

If the current history of breast cancer in your close relatives puts you in these categories, you may have an increased risk of developing breast cancer. You will be in either Category 2 (Moderately Increased Risk) or in Category 3 (Potentially High Risk). Make an appointment to see your general practitioner to find out which of these two categories you are in according to *Advice about familial aspects of breast cancer and ovarian cancer – A guide for health professionals*. More information about each of these two categories is given below:

### **Category 2 – Moderately Increased Risk:**

Although women in this group have a moderately increased risk of developing breast cancer compared with women in the general population, 75–90% will not get breast cancer at any time in their life.

- See your general practitioner without undue delay about any breast changes which are not normal for you
- Your general practitioner will advise you about how often you should be having mammograms and breast examinations
- If you think you need a more precise risk assessment, your general practitioner can consult a specialist cancer service or a family cancer clinic and can discuss their advice with you.

### **Category 3 – Potentially High Risk:**

Although women in this group have a potentially high risk of developing breast cancer compared with women in the general population, 50–75% will not get breast cancer at any time in their life.

- See your general practitioner without undue delay about any new breast changes which are not normal for you
- Your general practitioner may refer you to a cancer specialist. The specialist will help to plan how often you should be having mammograms and breast examinations, and will advise you about any other examinations that you may need to have
- If you want more information about your risk or that of your family, your doctor may refer you to a family cancer clinic for advice, appropriate counselling, management and genetic testing if it is appropriate for you.



## APPENDIX E SUMMARY OF USEFUL STRATEGIES TO PREPARE WOMEN FOR BREAST IMAGING

The following tables have been reproduced from *Psychosocial clinical practice guidelines: providing information, support and counselling for women from breast cancer*.<sup>78</sup> The psychosocial guidelines were developed for women with breast cancer. However, many of the strategies described in the guidelines could be used for women who do not receive a positive diagnosis. The tables below summarise useful strategies that could be used when preparing women for breast imaging and when giving test results. The topics covered include: preparing women for potentially threatening medical procedures; dealing with cultural issues; general interactional skills; and telling a woman she has breast cancer, a recurrence or metastasis.

**Table E1: General interactional skills**

The following skills should be considered in any consultation with women with breast cancer:

### **Supportive communication**

- Asking the woman if she would like someone to be with her during the consultation
- Show regard and concern for the woman by using appropriate verbal and non-verbal behaviour, including sitting attentively and facilitating the woman's responses
- Use verbal and non-verbal behaviours which are appropriate to a woman's age and cultural background
- Express empathy and listen actively
- Allow and encourage the woman to express her feelings (eg crying, talking about concerns, fears, anger, anxieties, etc)
- Handle embarrassing or disturbing topics directly and sensitively.

### **Delivering medical information in plain English**

- Assess a woman's understanding before providing additional information
- Explain difficult terms and avoid medical jargon
- Use explicit categorisation (provide information clearly grouped in specific topics).

### **Strategies to aid recall and understanding**

- Actively encourage questions and seek understanding
- Make use of simple diagrams and pictures where appropriate
- Repeat and summarise important information
- Reinforce important information by using one or more of the following aids:
  - Writing down relevant information
  - Taping the consultation as needed and if wanted
  - Sending the woman a summary letter as follow-up.

### **Ongoing support**

- Assess the woman's level of family or social support
- Provide the names and contact details of relevant persons or organisations to obtain more information
- Refer to a specialist breast nurse or other relevant professional for support as required.

Reproduced from the *NHMRC Psychosocial clinical practice guidelines: providing information, support and counselling for women with breast cancer*.<sup>78</sup>

**Table E2: Recommended steps involved in adequately preparing a woman for potentially threatening medical procedures**

These steps are recommended in conjunction with the general interactional skills summarised in Table E1.

**Before the Procedure**

- Explain why the procedure is needed and the expected outcome
- Ask how much detail she would like to know about the procedure before explaining it
- The information may include
  - Where the procedure might take place, and who will perform it
  - Any tests needed before the procedure
  - What the woman will need to do before the procedure
  - What the woman is likely to experience during and after the procedure
- Encourage her to talk about her concerns such as pain, fear, death, embarrassment
- Ask her what she thinks she can do to cope
- Enquire about, and reinforce, previous coping strategies (eg relaxation and imagery).

**During the Procedure**

- Provide information about what will be done and how it will feel
- Give the woman control, where possible (eg ask her to tell you when she is ready to begin)
- Encourage the use of coping strategies.

**After the procedure**

- Encourage the use of coping skills (eg relaxation methods and imagery)
- Encourage the woman to state her needs and reframe her complaints into requests
- Arrange follow-up and support.

Reproduced from the *NHMRC Psychosocial clinical practice guidelines: providing information, support and counselling for women with breast cancer*.<sup>78</sup>

**Table E3: Recommended steps involved in dealing with cultural issues**

- Book a trained interpreter from the Translating and Interpreting Services (TIS) if the woman is not proficient in English – ph: 13 14 50
- Explain the role of the interpreter and ensure that the woman agrees to their presence
- Talk directly to the woman rather than the interpreter, keep sentences short and pause after a few seconds to allow for interpretation
- Provide culturally-appropriate health care workers, when possible
- Provide a female medical professional or nurse, when possible
- Explain how confidentiality is achieved within the medical setting
- Ask how the woman feels about her disease and treatment, and what meaning it has for her within her culture
- Assess the woman's understanding of her disease, treatment and prognosis
- Ask about cultural or religious issues that may influence treatment
- Offer to discuss issues and treatment options with the woman's family
- Explain the importance of social support and encourage the woman to seek support from family, friends, support services and local cancer organisations
- Provide written information in the appropriate language, if available

- Arrange follow-up and support
- Always be aware of culturally-specific and individually-specific values, beliefs and modes of behaviour.

Reproduced from the *NHMRC Psychosocial clinical practice guidelines: providing information, support and counselling for women with breast cancer*.<sup>78</sup>

**Table E4: Recommended steps for telling a woman she has breast cancer, a recurrence or metastasis**

These steps are recommended in conjunction with the general interactional skills summarised in Table E1.

**1. Prior to discussing diagnosis, recurrence or metastases**

- Ensure the news is given in person, in a quiet, private place and allow enough uninterrupted time
- Encourage a second person to be present if appropriate
- Arrange to provide other methods to convey the information (eg written materials, video tapes, tapes of consultations, etc).

**2. When providing the information**

- Assess the woman's understanding of her condition and the woman's personal preference for information
- Briefly explain the process by which the diagnosis was reached
- Provide information simply and honestly, using lay terms without using euphemisms
- Avoid the notion that 'nothing can be done'
- Clearly indicate that the woman will have the final decision regarding her care.

**3. Emotional and supportive role**

- Encourage the woman to express her feelings (eg crying freely, talking about concerns, fears, anger, anxieties, etc) and respond to her feelings with empathy
- Address disturbing or embarrassing topics directly, and with sensitivity
- Assess the type and level of assistance that may be required, such as financial, transport or childcare assistance.
- Provide information about support services.

**4. Concluding the discussion**

- Summarise main points of the consultation and assess the woman's understanding
- Ask if there is anything further the woman would like to discuss
- Offer assistance to tell others difficult news
- Indicate your availability for contact to address any questions or concerns and arrange a further appointment to review the situation within a stated time period (eg within 24 hours to two weeks).

**5. After discussing a diagnosis, recurrence or metastases**

- Document information given to the woman and family members
- Let others know the extent of information given and your perception of the woman's understanding, particularly the woman's general practitioner.

Reproduced from the *NHMRC Psychosocial clinical practice guidelines: providing information, support and counselling for women with breast cancer*.<sup>78</sup>

## APPENDIX F      LABELLING OF IMAGING FILMS

The RANZCR's Diagnostic Mammography Standards<sup>3</sup> include the following labelling requirements:

- a) A permanent identification label, preferably a 'flash' label rather than a stick-on label with the following details:
  - Facility name
  - Patient's full name
  - Patient identification
  - Examination date
- b) Radiopaque markers indicating laterality (R/L) and projection/view (MLO/CC), which are:
  - Placed near the aspect of breast closest to the axilla
  - Placed on the cassette holder so they can be read from overhead
  - Large enough to be clearly readable without being distracting
  - Utilising standard abbreviations.
- c) Technologist's name or initials either on the identification label or in radiopaque letters on the cassette holder
- d) Cassette/screen identification by Arabic number written or pressed on screen to identify screens with artefacts or defects
- e) A radio-opaque dedicated mammographic unit identifier, eg MQAP number.

With the exception of the markers indicating laterality and view, all labels must be placed as far from the breast as possible.

Where initials are used on labels, eg technologists' initials, a log of names and identifying initials must be maintained.

## APPENDIX G     A STANDARDISED REPORT FOR BREAST IMAGING

It is recommended that the proposed standardised report be used for breast imaging. The use of standardised reporting helps to ensure that reports are concise, comprehensive and easy to understand. The minimum data to be included in a breast imaging report is provided below.

---

### 1. PATIENT IDENTIFICATION DETAILS:

---

### 2. REASON FOR EXAMINATION:

- The reason for the examination should be included on the referral. Further information can also be obtained from the woman.
- This should prompt the radiologist to correlate findings with any clinical signs/symptoms, even if the findings relate to normal breast tissue, fatty lobule, etc.

### BREAST DENSITY:

- Predominantly fatty, mixed fibroglandular tissue, dense, prostheses
- A statement in the narrative report regarding the radiographic density of the breast may be useful in conveying to the referring clinician a measure of the relative accuracy of the mammographic examination. For example, a dense breast may obscure underlying pathology on mammography, whereas nodules should be apparent in a fatty breast. It is recognised that there is inter-observer variation in reporting breast density. This item may be included in any narrative report but is not included as part of the standard checklist.

**Note: Breast density has not been given a number because it is recommended only for the narrative and the numbers should match the report form.**

---

### 3. NUMBER OF SIGNIFICANT IMAGING LESIONS:

A significant lesion is an abnormality detected on the clinical examination or breast imaging that requires further investigation. The standard report format has the ability to track up to three (3) significant lesions.

## IMAGING CHARACTERISTICS OF LESION #1:

---

### 4. LOCATION:

- Side: Right or left
- Site: Specify the most accurate location
  - For mammography - use location in breast, eg UO, UI, LO, LI, U central, L central
    - seen on one view only – specify upper, inner, outer, lower
  - For ultrasound - use o'clock and distance from nipple in mm
    - subareolar/central and axillary tail do not require o'clock
    - multicentric/widespread – indicate which regions are involved

*Because of the difficulties in translating MLO positioning into accurate o'clock positions, the ultrasound location is the preferred location if both ultrasound and mammography are performed.*

---

### 5. SIZE:

This should be stated in mm. Use the most accurate maximum diameter of mass and maximum extent of abnormality for calcification and distortion. Usually, ultrasound will give the most accurate size measurement for masses.

---

### 6. MAMMOGRAPHY CHARACTERISTICS:

**State only if present and a significant finding.**

**Not necessary to state if not present.**

- Not performed
  - No lesion seen
  - Mass: if present give description of characteristics (see Table G2)
  - Significant calcification: if present give description of characteristics (see Table G2)
  - Architectural distortion
  - Asymmetric density
  - Other findings: specify.
- 

### 7. ULTRASOUND CHARACTERISTICS:

**State only if present and a significant finding.**

**Not necessary to state if not present.**

- Not performed
  - Mammographic/clinical abnormality not visualised
  - Mass: if present give description of characteristics (see Table G2)
  - Distortion
  - Calcification without mass
  - Other findings: specify
- 

### 8. DO IMAGING FINDINGS CORRELATE WITH CLINICAL SIGNS/SYMPTOMS?:

Yes / No / No clinical signs

---

## 9. COMBINED IMAGING DIAGNOSIS:

Give a single imaging diagnosis, if possible, based upon mammographic and ultrasound findings. If there is a differential, this may be given, but try to indicate the most likely diagnosis.

---

## 10. CLASSIFICATION:

It is recommended that the classification apply to all reported lesions, and the levels of suspicion range from 1–5 as follows:

### 1. No significant abnormality

- There is no significant imaging abnormality
- Standard format checklist is not required
- If there is a clinical symptom, and there are no imaging abnormalities to explain it this should be stated in the report
- This classification does not preclude biopsy of any clinically suspicious area.

### 2. Benign findings

- No further imaging is required
- Standard-format checklist is optional
- Correlation of findings with clinical symptoms, if present, should be stated in the report
- This classification does not preclude biopsy of any clinically suspicious area.

### 3. Indeterminate/equivocal findings

- Requires further investigation, usually fine needle aspiration (FNA) cytology/core biopsy
- Management should be based on the outcome of the triple test
- There may be a limited role for early follow-up (eg inflammation)
- Further investigation will almost always resolve the indeterminate nature of the lesion
- Correlation of findings with clinical symptoms, if present, should be stated in the report
- This classification does not preclude biopsy of any clinically suspicious area.

### 4. Suspicious findings of malignancy

- Requires further investigation
- May require excisional biopsy
- Correlation of findings with clinical symptoms, if present, should be stated in the report.

### 5. Malignant findings

- Requires further investigation even if non-excision (percutaneous) sampling is benign
- Correlation of findings with clinical symptoms, if present, should be stated in the report.

When reporting the classification, both the number and the description of the classification should be stated, for example, ‘Category 2. Benign findings’ or ‘Category 3. Indeterminate/equivocal findings’.

---

## 11. RECOMMENDATION FOR FURTHER IMAGING/INVESTIGATION:

Lesion #2: as per lesion #1

Lesion #3: as per lesion #1

**Note: if there is a clinical symptom, the reason for examination should be lesion #1.**

**Table G1 Breast imaging summary**

A checklist of items to be included in the proposed standardised breast imaging report:

**Note: This form does not have to be used for classification 1 and is optional for classification 2.**

**1. Patient identification details:**

**2. Reason for examination:**

**3. Number of significant imaging lesions:**

	Lesion #1	Lesion #2	Lesion #3
<b>4. Location:</b>			
Side			
Site			
Distance from nipple (U/S)			
<b>5. Size (mm):</b>			
<b>6. Mammography characteristics:</b>			
Not performed			
No abnormality			
Abnormality (see Table G2)			
<b>7. Ultrasound characteristics:</b>			
Not performed			
No abnormality			
Abnormality (see Table G2)			
<b>8. Correlation with clinical findings:</b>			
Yes/No/No clinical findings			
<b>9. Combined imaging diagnosis:</b>			
<b>10. Classification:</b>			
1. No significant abnormality			
2. Benign findings			
3. Indeterminate/equivocal findings			
4. Suspicious findings of malignancy			
5. Malignant findings			
<b>11. Recommendation for further investigation:</b>			



## **Table G2            Descriptors for mammography and ultrasound findings**

*Use only if present. Do not give negative findings.*

### **Mammography characteristics of abnormalities**

- Mass:
  - Shape: round/ovoid, lobulated, irregular
  - Margins: sharply defined, poorly defined, spiculated
  - Associated with calcifications: present/not present. If present, do calcifications extend beyond the mass.
- Significant Calcification:
  - Distribution: single cluster, multiple clusters, ductal, segmental, widespread
  - Shape: pleomorphic, granular, casting/linear/branching
  - Associated mammographic density, present/not present
- Architectural distortion
- Asymmetric density
- Other findings: specify.

### **Ultrasound characteristics of abnormalities**

- Mass:
  - Echotexture: cyst, solid, complex
  - Shape: round/oval, lobulated, irregular
  - Margins: sharply defined, poorly defined, spiculated
  - Surrounding tissues: normal / abnormal
  - Calcification: present/not present
- Architectural distortion
- Calcification not in mass
- Other findings: specify.

## **APPENDIX H      CONTACTS FOR TRAINING AND CONTINUING EDUCATION**

Training and continuing education in breast imaging is available through a number of organisations in Australia:

### **Australian Institute of Radiography (AIR)**

Phone: 03 9419 3336  
Fax: 03 9416 0783  
Email: [info@a-i-r.com.au](mailto:info@a-i-r.com.au)  
Website: [www.a-i-r.com.au](http://www.a-i-r.com.au)

### **Australian Society for Breast Disease**

Phone: 07 3847 1946  
Fax: 07 3847 7563  
Website: [www.asbd.org.au](http://www.asbd.org.au)

### **Australasian Society of Breast Physicians**

Phone: 07 4031 6482  
Fax: 07 4041 1105

### **Australasian Society for Ultrasound in Medicine**

Phone: 02 9958 7655  
Fax: 02 9958 8002  
Email: [asum@asum.com.au](mailto:asum@asum.com.au)  
Website: [www.asum.com.au](http://www.asum.com.au)

### **Breast Interest Group of the RANZCR**

Phone: 02 9268 9777  
Fax: 02 9268 9799  
Email: [ranzcr@ranzcr.edu.au](mailto:ranzcr@ranzcr.edu.au)

### **Breast Imaging Reference Group of the RANZCR**

Phone: 02 9268 9777  
Fax: 02 9268 9799  
Email: [ranzcr@ranzcr.edu.au](mailto:ranzcr@ranzcr.edu.au)

### **International Breast Ultrasound School**

Phone: 02 9371 7094  
Fax: 02 9371 9828  
Website: [www.ibus.org](http://www.ibus.org)

### **National Breast Cancer Centre**

Phone: 02 9036 3030  
Fax: 02 9036 3077  
Website: [www.nbcc.org.au](http://www.nbcc.org.au)

**Royal Australasian College of Surgeons**

Phone: 03 9249 1200  
Fax: 03 9249 1219  
Email: [surgeon.sec@rcpa.edu.au](mailto:surgeon.sec@rcpa.edu.au)  
Website: [www.racs.edu.au](http://www.racs.edu.au)

**Royal Australian and New Zealand College of Radiologists (RANZCR)**

Phone: 02 9268 9777  
Fax: 02 9268 9799  
Email: [ranzcr@ranzcr.edu.au](mailto:ranzcr@ranzcr.edu.au)  
Website: [www.ranzcr.edu.au](http://www.ranzcr.edu.au)

**BreastScreen Australian Capital Territory**

Phone: 02 6205 1540  
Fax: 02 6205 1394  
Website: [www.communitycare.act.gov.au/womens/breastscreen.html](http://www.communitycare.act.gov.au/womens/breastscreen.html)

**BreastScreen New South Wales**

Phone: 02 9845 8855  
Fax: 02 9845 8355  
Website: [www.bsnsw.org.au](http://www.bsnsw.org.au)

**BreastScreen Northern Territory**

Phone: 08 8922 5501  
Fax: 08 8922 5511  
Website: [www.nt.gov.au/health/comm\\_health/womens\\_health/breastscreen\\_nt.shtml](http://www.nt.gov.au/health/comm_health/womens_health/breastscreen_nt.shtml)

**BreastScreen Queensland**

Phone: 07 3275 6777  
Fax: 07 3275 6790  
Website: [www.health.qld.gov.au/breastscreen/](http://www.health.qld.gov.au/breastscreen/)

**BreastScreen South Australia**

Phone: 08 8300 1800  
Fax: 08 8373 4395  
Website: [www.breastscreen.sa.gov.au](http://www.breastscreen.sa.gov.au)

**BreastScreen Tasmania**

Phone: 03 6233 6356  
Fax: 03 6233 3453

**BreastScreen Victoria**

Phone: 03 9660 6888  
Fax: 03 9662 3881  
Website: [www.breastscreen.org.au](http://www.breastscreen.org.au)

**BreastScreen Western Australia**

Phone: 08 9237 6900

Fax: 08 9237 6999

Website: [www.breastscreen.health.wa.gov.au](http://www.breastscreen.health.wa.gov.au)

**International website links**

Training and continuing education in breast imaging is also available through a number of international organisations. The website links are listed below.

**American College of Radiology**

[www.acr.org/](http://www.acr.org/)

**European Federation of Societies for Ultrasound in Medicine and Biology**

[www.efsumb.org](http://www.efsumb.org)

**International Breast Ultrasound School**

[www.ibus.org/education](http://www.ibus.org/education)

**Mammography Education Inc**

[www.mammographyed.com](http://www.mammographyed.com)

**Royal College of Radiology (United Kingdom)**

[www.rcr.ac.uk](http://www.rcr.ac.uk)

**Society of Breast Imaging (United States)**

[www.sbi-online.org/Education.htm](http://www.sbi-online.org/Education.htm)

## **GLOSSARY**

### **Architectural disturbances/ distortions:**

The normal architecture is distorted with no definite mass visible. This includes spiculations radiating from a point and focal retraction or distortion of the edge of the parenchyma

### **Asymmetric densities:**

A localised density on one side only

### **BRCA1:**

Breast cancer gene 1. A gene which is defective in about 2% of women with breast cancer

### **Breast symptom:**

A change in the breast including a lump, lumpiness, any change in shape or dimpling of the skin, nipple discharge, nipple inversion and/or pain

### **Calcification:**

The deposition of calcium salts in body tissues. In the breast, calcification can be seen in normal and abnormal ducts and in association with some carcinomas, both invasive and in situ

### **Compression spot views:**

X-ray of a small area of the breast that has been compressed by a paddle device

### **Cleavage view:**

Mammographic view that images the most medial portions of both breasts

### **Cleopatra view:**

Mammographic view that images the axillary tail of the breast

### **Coned compression:**

See 'compression spot views'

**Cranio-caudal (CC):**

One of the two standard views for two-view mammography. The CC view will show virtually all but the most lateral and axillary part of the breast. The CC view should show the medial border of the breast, some of the axillary tail of the breast and the nipple in profile and sometimes the pectoral muscle shadow on posterior edge of the breast

**Cyst:**

A closed cavity or sac lined by epithelium, normal or abnormal, which contains liquid or semisolid material

**Dedicated breast coil:**

A coil used during magnetic resonance imaging that is shaped to obtain optimal images of the breast

**Density:**

A radio-opaque area seen on a mammogram

**Ductal carcinoma in situ (DCIS):**

An abnormal proliferative condition of epithelial cells in the mammary ducts. These cells display cytological features of invasive carcinoma, but unlike invasive carcinoma, DCIS is contained within the ducts

**Exclusion views / Eklund views:**

Views which exclude augmentation prostheses from the mammographic image

**Extracapsular rupture:**

When silicon from prostheses has tracked in to the surrounding breast tissue beyond the fibrous capsule

**Extravasated silicone:**

The discharge or escape of silicone into the surrounding area from a breast implant capsule

**False negative rate:**

The number of examinations with cancer present which were incorrectly called normal expressed as a percentage of the total number of examinations

**False negative:**

The number of examinations with cancer present which were incorrectly called normal expressed as a percentage of the total number of examinations

**False positive rate:**

The number of normal examinations which were incorrectly called positive expressed as a total number of the examinations

**False positive:**

A test result that is falsely identified as positive, ie given a malignant result, that subsequently turns out to be benign

**Fat necrosis:**

A condition (usually post traumatic) in which the neutral fat in the cells of adipose tissue are split into fatty acids and glycerol

**Gadolinium enhanced magnetic resonance imaging (MRI):**

Magnetic resonance imaging using an intravenous injection of the contrast agent Gadolinium to improve detection of malignant tumours. Gadolinium is a rare metallic element with a characteristic spectrum

**Galactography:**

Radiography of the mammary ducts after injection of a radio-opaque substance into the duct system

**Lobular carcinoma in situ (LCIS):**

A non-invasive multicentric proliferation of the epithelial cells in the lobules and terminal ducts of the breast

**Magnification spot Views:**

X-ray of a small area of the breast that has been magnified. This is used to assess calcification and other fine detail

**Mass:**

A space-occupying lesion seen in two different projections. If a potential mass is seen in only a single projection it should be called a *density* until its three-dimensionality is confirmed

**Medio-lateral oblique (MLO):**

One of the two standard views for mammography, in which the X-ray beam passes obliquely from medial to lateral in the breast. This view aims to show a wedge of the pectoral muscle to nipple level, the nipple in profile and the infra-mammary angle clearly demonstrated

**Microcalcifications:**

Tiny calcifications that range from 50 to several hundred microns in diameter. These may be an important early indication of breast cancer

**Microfocus magnification:**

The small focal spot of an X-ray machine (approx. 0.15 mm) used for magnification films (standard focal spot is approx. 0.4 mm)

**Non-excision (percutaneous) biopsy:**

A sample of tissue or cells taken/removed from the body, through the skin using a needle

**Optical density:**

A measure of the amount of blackening on an X-ray film. Higher film density promotes improved demonstration of dense breast tissue

**Radio-opaque markers:**

A marker that can be seen when using an X-ray technique. Such a marker can be placed at the tumour bed during surgery and allows the tumour bed to be accurately identified on any subsequent imaging

**Resolution:**

A measure of how much spatial and contrast detail a device can print or display



**Sensitivity:**

The ability of a test to detect a disease; a test with a sensitivity of 90% will give a positive test result in nine out of ten cases of disease present in the population tested

**Specificity:**

The ability of a test to exclude people who do not have disease. A test with a specificity of 90% will give a negative result in nine out of ten non-diseased people tested

**Stereotactic localisation:**

Precise three-dimensional localisation of a structure within the breast by taking two X-ray images and computing the depth of the abnormality

**Tangents:**

Fields (radiotherapy target areas) that are planned in such a way that the irradiation of a sector of the chest wall following mastectomy or chest wall and breast following breast conserving surgery minimises irradiation of the underlying lung

## REFERENCE LIST

1. National Health and Medical Research Council. *A guide to the development, implementation and evaluation of clinical practice guidelines*. Canberra: Australian Government Publishing Service, 1998.
2. BreastScreen Australia. *National Accreditation Standards. BreastScreen Australia Quality Improvement Program* (in preparation). BreastScreen Australia, 2002.
3. The Royal Australian and New Zealand College of Radiologists. *Diagnostic Mammography Standards 5.1*. The Royal Australian and New Zealand College of Radiologists (last updated 2001), 2001.
4. The Royal Australian and New Zealand College of Radiologists. *RANZCR/NATA Medical Imaging Accreditation Program*. [www.ranzcr.edu.au/open/program.htm](http://www.ranzcr.edu.au/open/program.htm) The Royal Australian and New Zealand College of Radiologists (last updated 1999).
5. The Royal Australian and New Zealand College of Radiologists. *Accreditation Standards for Diagnostic and Interventional Radiology. Version 5.1*. [www.ranzcr.edu.au/open/standard.htm](http://www.ranzcr.edu.au/open/standard.htm) (last updated 2001).
6. The Royal Australian and New Zealand College of Radiologists. *Statement on Mammography and Screening for Women who carry BrCA1 Mutations*. [www.racr.edu.au/open/pol7\\_2.htm](http://www.racr.edu.au/open/pol7_2.htm) The Royal Australian and New Zealand College of Radiologists (last updated 2000).
7. The Royal Australian and New Zealand College of Radiologists. *Guidelines on Mammography Screening for Women with Prostheses*. [www.racr.edu.au/open/pol7\\_1.htm](http://www.racr.edu.au/open/pol7_1.htm) The Royal Australian and New Zealand College of Radiologists (last updated 2000).
8. The Royal Australian and New Zealand College of Radiologists. *Position on teleradiology*. [www.ranzcr.edu.au/open/pol\\_teleradiology.htm](http://www.ranzcr.edu.au/open/pol_teleradiology.htm) (last updated 1997).

9. iSource National Breast Cancer Centre. *Breast changes*. Woolloomooloo (NSW): iSource National Breast Cancer Centre, 2000.
10. Australian Institute of Health and Welfare, Australasian Association of Cancer Registries. *Cancer in Australia 1996 – Incidence and Mortality Data for 1996 and Selected Data for 1997 and 1998 Cancer Series*. Canberra: Australian Institute of Health and Welfare, 1999.
11. Ambrogetti D, Ciatto S, Catarzi S, Muraca MG. The combined diagnosis of male breast lesions: a review of a series of 748 consecutive cases. *Radiol Med (Torino)* 1996;91:356–9.
12. Board of the Faculty of Clinical Radiology, The Royal College of Radiology. *Guidance on screening and symptomatic breast imaging*. London: Royal College of Radiologists, 1999.
13. American College of Radiology. *ACR Standard for the performance of the diagnostic mammography*. Reston, VA: ACR, 1999.
14. American College of Radiology. *Mammography quality control manual*. Reston, VA: American College of Radiology, 1999.
15. American College of Radiology. *ACR Standards for the performance of breast ultrasound examination*. Reston, VA: American College of Radiology, 1999.
16. Department of Health and Human Services. 21 CFR Parts 16 and 900. Quality Mammography Standards; Final Rule. *Federal Register* 1997;62:55983–92.
17. Woodward V, Webb C. Women’s anxieties surrounding breast disorders: a systematic review of the literature. *J Adv Nurs* 2001;33:29–41.
18. Poole K, Hood DB, Monypenny IJ, Sweetland H et al. Psychological distress associated with waiting for results of diagnostic investigations for breast disease. *The Breast* 1999;8:334–8.

19. Brett J, Austoker J, Ong G. Do women who undergo further investigation for breast screening suffer adverse psychological consequences? A multi-centre follow-up study comparing different breast screening result groups five months after their last breast screening appointment. *J Public Health Med* 1998;20:396–403.
20. Deane KA, Degner LF. Information needs, uncertainty, and anxiety in women who had a breast biopsy with benign outcome. *Cancer Nurs* 1998;21:117–26.
21. Poole K. The emergence of the ‘waiting game’: a critical examination of the psychosocial issues in diagnosing breast cancer. *J Adv Nurs* 1997;25:273–81.
22. Sterns EE. The abnormal mammogram in women with clinically normal breasts [see comments]. *Can J Surg* 1995;38:168–72.
23. Barratt AL, Cockburn J, Lowe J, Paul C et al. *Report on the 1996 Breast Health Survey*. Kings Cross: National Breast Cancer Centre, 1997.
24. International Breast Ultrasound School and Albert-Ludwigs-Universität Freiburg. *The 2nd International breast imaging update IBIU ‘99*. Baden, Switzerland: International Breast Ultrasound School, 1999.
25. NHMRC National Breast Cancer Centre. *The investigation of a new breast symptom: a guide for general practitioners*. Woolloomooloo (NSW): NHMRC National Breast Cancer Centre, 1997.
26. Australian Institute of Health and Welfare, Australasian Association of Cancer Registries, National Breast Cancer Centre. *Breast cancer in Australian women, 1982–1996*. Canberra: Australian Institute of Health and Welfare, 1999.
27. Hill D, Jamrozik K, White V, Collins J et al. *Surgical management of breast cancer in Australia in 1995*. Woolloomooloo (NSW): National Breast Cancer Centre, 1999.

28. Houssami N, Irwig L. Likelihood ratios for clinical examination, mammography, ultrasound and fine needle biopsy in women with breast problems. *The Breast* 1998;7:85–90.
29. Tulloh B, Goldsworthy M. Breast cancer management: a rural perspective. *Med J Aust* 1997;166:26–9.
30. Grunfeld E, Mant D, Yudkin P, Adewuyi-Dalton R et al. Routine follow-up of breast cancer in primary care: randomised trial [see comments]. *BMJ* 1996;313:665–9.
31. Gillis CR, Hole DJ. Survival outcome of care by specialist surgeons in breast cancer: a study of 3786 patients in the west of Scotland [see comments]. *BMJ* 1996;312:145–8.
32. Sainsbury R, Haward B, Rider L, Johnston C, Round C. Influence of clinician workload and patterns of treatment on survival from breast cancer. *Lancet* 1995;345:1265–70.
33. Irwig L, Macaskill P. *Evidence relevant to guidelines for the investigation of breast symptoms*. Woolloomooloo (NSW): NHMRC National Breast Cancer Centre, 1997.
34. Kricker A, Clements M. *An examination of procedures reimbursed under Medicare for breast disease and breast cancer in Australia, 1985 to 1996*. Kings Cross NSW: National Breast Cancer Centre, 1999.
35. Health Insurance Commission. *Medicare Benefits Schedule (MBS) Statistics*. [www.hic.gov.au/cgi-bin/broker.exe](http://www.hic.gov.au/cgi-bin/broker.exe) (last updated 2000).
36. Tabar L, Fagerberg G, Duffy S, Day N. The Swedish two county trial of mammographic screening for breast cancer: recent results and calculation of benefit. *J Epidemiol Community Health* 1989;43:107–14.
37. Shapiro S, Venet W, Strax P, Venet L, Roeser R. Ten to fourteen year effect of screening on breast cancer mortality. *J Natl Cancer Inst* 1982;69:349–55.

38. Andersson I, Aspegren K, Janzon L, Landberg T et al. Mammographic screening and mortality from breast cancer: the Malmo mammographic screening trial. *BMJ* 1988;297:943–8.
39. Irwig L, Glasziou P, Barratt AL, Salkeld G. *Review of the evidence about the value of mammographic screening in 40–49 year old women*. Woolloomooloo (NSW): National Breast Cancer Centre, 1997.
40. NHMRC National Breast Cancer Centre, Early Detection and Diagnosis Working Group. *Screening women aged 40–49 years: a summary of the evidence for health professionals*. Woolloomooloo (NSW): NHMRC National Breast Cancer Centre, 1998.
41. iSource National Breast Cancer Centre. *Clinical practice guidelines for the management of early breast cancer: 2nd edition*. Woolloomooloo NSW: iSource National Breast Cancer Centre, 2002.
42. National Breast Cancer Centre. *Clinical practice guidelines for the management of ductal carcinoma in situ, lobular carcinoma in situ and atypical hyperplasia of the breast. First Edition*. (in preparation). Camperdown NSW: National Breast Cancer Centre, 2002.
43. NHMRC National Breast Cancer Centre. *Advice about familial aspects of breast cancer and ovarian cancer: a guide for health professionals*. Woolloomooloo (NSW): NHMRC National Breast Cancer Centre, 2000.
44. Feig SA, Hendrick RE. Radiation risk from screening mammography of women aged 40–49 years. *J Natl Cancer Inst* 1997; 22:119–24.
45. Irwig L, Macaskill P. *Evidence relevant to guidelines for the investigation of breast symptoms*. Woolloomooloo (NSW): NHMRC National Breast Cancer Centre, 1997.
46. Britton PD, McCann J. Needle biopsy in the NHS Breast screening Programme 1996–1997: how much and how accurate? *The Breast* 1999;8:5–11.

47. Pinder SE, Elston CW, Ellis IO. The role of pre-operative diagnosis in breast cancer. *Histopathology* 1996;28:563–6.
48. Krickler A, Armstrong B, Smith C, Bilous M, et al. An audit of breast cancer pathology reporting in Australia in 1995. *Br J Cancer* 1999;80:563–8.
49. Nakhleh RE, Jones B, Zarbo RJ. Mammographically directed breast biopsies: a College of American Pathologists Q-Probes study of clinical physician expectations and of specimen handling and reporting characteristics in 434 institutions. *Arch Pathol Lab Med* 1997;121:11–8.
50. Zarbo RJ. Interinstitutional assessment of colorectal carcinoma surgical pathology report adequacy. A College of American Pathologists Q-Probes study of practice patterns from 532 laboratories and 15,940 reports [see comments]. *Arch Pathol Lab Med* 1992;116:1113–9.
51. Zarbo RJ. The oncologic pathology report. Quality by design. *Arch Pathol Lab Med* 2000;124:1004–10.
52. NHMRC iSource National Breast Cancer Centre. *Clinical practice guidelines for the management of advanced breast cancer*. Woolloomooloo: iSource National Breast Cancer Centre, 2001.
53. NHMRC National Breast Cancer Centre. *Radiotherapy and breast cancer*. Kings Cross, NSW: NHMRC National Breast Cancer Centre, 1999.
54. Harrington KJ, Harrison M, Bayle P, Evans K et al. Surgical clips in planning the electron boost in breast cancer: a qualitative and quantitative evaluation [see comments]. *Int J Radiat Oncol Biol Phys* 1996;34:579–84.
55. Krawczyk JJ, Engel B. The importance of surgical clips for adequate tangential beam planning in breast conserving surgery and irradiation. *Int J Radiat Oncol Biol Phys* 1999;43:347–50.

56. Zissiadis Y, Langlands AO, Barraclough B, Boyages J. Breast conservation: long-term results from Westmead Hospital. *Aust NZJ Surg* 1997;67:313–9.
57. Smith TJ, Davidson NE, Schapira DV, Grunfeld E et al. American Society of Clinical Oncology 1998 update of recommended breast cancer surveillance guidelines. *J Clin Oncol* 1999;17:1080–2.
58. Snee M. Follow-up of women treated for breast cancer. *Clin Oncol (R Coll Radiol)* 1996;8:85–9.
59. Rojas MP, Telaro E, Russo A, Fossati R et al. Follow-up strategies for women treated for early breast cancer (Cochrane Review). *Cochrane Database Syst Rev* 2000;4:CD001768.
60. Brenner RJ, Pfaff JM. Mammographic features after conservation therapy for malignant breast disease: serial findings standardized by regression analysis. *AJR Am J Roentgenol* 1996;167:171–8.
61. Philpotts LE, Lee CH, Haffty BG, Lange RC, Tocino I. Mammographic findings of recurrent breast cancer after lumpectomy and radiation therapy: comparison with the primary tumor. *Radiology* 1996;201:767–71.
62. Giess CS, Keating DM, Osborne MP, Rosenblatt R. Local tumor recurrence following breast-conservation therapy: correlation of histopathologic findings with detection method and mammographic findings. *Radiology* 1999;212:829–35.
63. Holli K, Saaristo R, Isola J, Hyoty M, Hakama M. Effect of radiotherapy on the interpretation of routine follow-up mammography after conservative breast surgery: a randomised study. *Br J Cancer* 1998;78:542–5.
64. Chu FC, Kaufmann TP, Dawson GA, Kim YS et al. Radiation therapy of cancer in prosthetically augmented or reconstructed breasts. *Radiology* 1992;185:429–33.



65. Leibman AJ, Styblo TM, Bostwick J. Mammography of the postreconstruction breast. *Plastic and Reconstructive Surgery* 1998;99:698–704.
66. Mund DF, Wolfson P, Gorczyca DP, Fu YS et al. Mammographically detected recurrent nonpalpable carcinoma developing in a transverse rectus abdominus myocutaneous flap. *Cancer* 1994;74:2804–7.
67. Fajardo LL, Roberts CC, Hunt KR. Mammographic surveillance of breast cancer patients: should the mastectomy site be imaged? *AJR Am J Roentgenol* 1993;161:953–5.
68. Lyons R, Payne C, McCabe M, Fielder C. Legibility of doctors' handwriting: quantitative comparative study. *BMJ* 1998;317:863–4.
69. Winslow EH, Nestor VA, Davidoff SK, Thompson PG, Borum JC. Legibility and completeness of physicians' handwritten medication orders [published erratum appears in *Heart Lung* 1997 May – Jun;26(3):203]. *Heart Lung* 1997;26:158–64.
70. Commonwealth Department of Health and Aged Care. *Medicare Benefits Schedule: 1 November 2001*. <http://www.health.gov.au/pubs/mbs/index.htm> Commonwealth Department of Health and Aged Care, (last updated 2001).
71. Gilbert FJ, Cordiner CM, Affleck IR, Hood DB et al. Breast screening: the psychological sequelae of false-positive recall in women with and without a family history of breast cancer. *Eur J Cancer* 1998;34:2010–4.
72. Lindfors KK, O'Connor J, Acredolo CR, Liston SE. Short-interval follow-up mammography versus immediate core biopsy of benign breast lesions: assessment of patient stress. *AJR Am J Roentgenol* 1998;171:55–8.
73. DeKeyser FG, Wainstock JM, Rose L, Converse PJ, Dooley W. Distress, symptom distress, and immune function in women with suspected breast cancer. *Oncol Nurs Forum* 1998;25:1415–22.

74. Ong G, Austoker J, Brett J. Breast screening: adverse psychological consequences one month after placing women on early recall because of a diagnostic uncertainty. A multicentre study. *J Med Screen* 1997;4:158–68.
75. Rimer BK, Bluman LG. The psychosocial consequences of mammography. *J Natl Cancer Inst Monogr* 1997;131–8.
76. Benedict S, Williams RD, Baron PL. Recalled anxiety: from discovery to diagnosis of a benign breast mass. *Oncol Nurs Forum* 1994;21:1723–7.
77. Lerman C, Trock B, Rimer BK, Boyce A et al. Psychological and behavioral implications of abnormal mammograms. *Ann Intern Med* 1991;114:657–61.
78. NHMRC National Breast Cancer Centre. *Psychosocial clinical practice guidelines: providing information, support and counselling for women with breast cancer*. Canberra: National Health and Medical Research Council, 1999.
79. iSource National Breast Cancer Centre. *Do you have a breast change?* Woolloomooloo, NSW: iSource National Breast Cancer Centre, 2002.
80. Macmillan RD. Screening women with a family history of breast cancer – results from the British Familial Breast Cancer Group. *Eur J Surg Oncol* 2000;26:149–52.
81. Bassett LW. Imaging of breast masses. *Radiol Clin North Am* 2000;38:669–viii.
82. Bassett LW, Ysrael M, Gold RH, Ysrael C. Usefulness of mammography and sonography in women less than 35 years of age. *Radiology* 1991;180:831–5.
83. Brand IR, Sapherson DA, Brown TS. Breast imaging in women under 35 with symptomatic breast disease. *Br J Radiol* 1993;66:394–7.

84. Seltzer MH. The significance of breast complaints as correlated with age and breast cancer. *Am Surg* 1992;58:413–7.
85. Echlund GW. *The Art of Mammographic Positioning, in Radiological Diagnosis of Breast Diseases*. Berlin: Springer, 1997.
86. Faulk RM, Sickles EA. Efficacy of spot compression-magnification and tangential views in mammographic evaluation of palpable breast masses. *Radiology* 1992;185:87–90.
87. Feig SA. The importance of supplementary mammographic views to diagnostic accuracy. *AJR Am J Roentgenol* 1988;151:40–1.
88. Berkowitz JE, Gatewood OM, Gayler BW. Equivocal mammographic findings: evaluation with spot compression. *Radiology* 1989;171:369–71.
89. Fornage BD, Sneige N, Faroux MJ, Andry E. Sonographic appearance and ultrasound-guided fine-needle aspiration biopsy of breast carcinomas smaller than 1 cm<sup>3</sup>. *J Ultrasound Med* 1990;9:559–68.
90. Parker SH, Stavros AT, Dennis MA. Needle biopsy techniques. *Radiol Clin North Am* 1995;33:1171–86.
91. Ciatto S, Bravetti P, Cariaggi P. Significance of nipple discharge clinical patterns in the selection of cases for cytologic examination. *Acta Cytol* 1986;30:17–20.
92. Groves A, Carr M, et al. An audit of cytology in the evaluation of nipple discharge: a retrospective study of 10 year experience. *The Breast* 1996;5:96–9.
93. Propeck PA, Scanlan KA. Utility of axillary views in postmastectomy patients. *Radiology* 1993;187:769–71.
94. Sadowsky NL, Semine A, Harris JR. Breast imaging. A critical aspect of breast conserving treatment. *Cancer* 1990;65:2113–8.

95. Hassell PR, Olivotto IA, Mueller HA, Kingston GW, Basco VE. Early breast cancer: detection of recurrence after conservative surgery and radiation therapy. *Radiology* 1990;176:731–5.
96. Stomper PC, Recht A, Berenberg AL, Jochelson MS, Harris JR. Mammographic detection of recurrent cancer in the irradiated breast. *AJR Am J Roentgenol* 1987;148:39–43.
97. Warneke J, Grossklaus D, Davis J, Stea B et al. Influence on local treatment on the recurrence rate of ductal carcinoma in situ. *J Am Coll Surg* 1995;180:683–8.
98. Heywang-Kobrunner SH, Schlegel A, Beck R, Wendt T et al. Contrast-enhanced MRI of the breast after limited surgery and radiation therapy. *J Comput Assist Tomogr* 1993;17:891–900.
99. DeBruhl ND, Gorczyca DP, Ahn CY, Shaw WW, Bassett LW. Silicone breast implants: US evaluation. *Radiology* 1993;189:95–8.
100. Everson LI, Parantainen H, Detlie T, Stillman AE et al. Diagnosis of breast implant rupture: imaging findings and relative efficacies of imaging techniques. *AJR Am J Roentgenol* 1994;163:57–60.
101. Gorczyca DP, Sinha S, Ahn CY, DeBruhl ND et al. Silicone breast implants in vivo: MR imaging. *Radiology* 1992;185:407–10.
102. iSource National Breast Cancer Centre. *National Communication Skills Training Strategy*. Woollmooloo (NSW): iSource National Breast Cancer Centre, 2000.
103. Lowe J, Balanda K, Del Mar C, Hawes E. Psychologic distress in women with abnormal findings in mass mammography screening. *Cancer* 1999;85 :1114–8.
104. Australian Cancer Network Pathology Working Party. *The pathology reporting of breast cancer: a guide for pathologists, surgeons and radiologists*. Sydney: Australian Cancer Network, 1997.

105. Robboy SJ, Bentley RC, Krigman H, Silverberg SG et al. Synoptic reports in gynecologic pathology. *Int J Gynecol Pathol* 1994;13:161–74.
106. Nochomovitz LE. Application of synoptic reports [letter; comment]. *Arch Pathol Lab Med* 1998;122:493–4.
107. American College of Radiology. *Breast imaging reporting and data system (BI-RADS) 2nd ed.* Reston, VA: ACR, 2000.
108. Baker JA, Kornguth PJ, Soo MS, Walsh R, Mengoni P. Sonography of solid breast lesions: observer variability of lesion description and assessment. *AJR Am J Roentgenol* 1999;172:1621–5.
109. Berg WA, Campassi C, Langenberg P, Sexton MJ. Breast Imaging Reporting and Data System: inter-and intraobserver variability in feature analysis and final assessment. *AJR Am J Roentgenol* 2000;174:1769–77.
110. Baker JA, Kornguth PJ, Floyd CE, Jr. Breast imaging reporting and data system standardized mammography lexicon: observer variability in lesion description [see comments]. *AJR Am J Roentgenol* 1996;166:773–8.
111. D’Orsi CJ, Kopans DB. Mammography interpretation: the BI-RADS method [editorial]. *Am Fam Physician* 1997;55:1548–50, 1552.
112. Kemp KI, Jackson GL. A simple classification system for mammographic reporting. *Radiology* 1987;165:319–22.
113. Lee S, Lo C, Wang C, Chung P et al. A computer-aided design mammography screening system for detection and classification of microcalcifications [In Process Citation]. *Int J Med Inf* 2000;60:29–57.
114. Heilbrunn KS. The American College of Radiology’s mammography lexicon: barking up the wrong tree? [comment]. *AJR Am J Roentgenol* 1994;162:593–4.

115. Roche NA, Given-Wilson RM, Thomas VA, Sacks NP. Assessment of a scoring system for breast imaging [see comments]. *Br J Surg* 1998;85:669–72.
116. Spigelman AD. Assessment of a scoring system for breast imaging [letter; comment]. *Br J Surg* 1998;85:1722.
117. Skaane P, Amlie E. A personal-computer semiautomated report-coding system for diagnostic mammography. *Eur J Radiol* 1993;17:43–6.
118. Skaane, P. *Ultrasound as adjunct to mammography in the evaluation of breast tumors*. Oslo, Norway: Department of Radiology, Ullevaal University Hospital, 1999.
119. Blais C, Samson L. The radiologic report: a realistic approach. *Can Assoc Radiol J* 1995;46:19–22.
120. Sierra AE, Bisesi MA, Rosenbaum TL, Potchen EJ. Readability of the radiologic report. *Invest Radiol* 1992;27:236–9.
121. Clinger NJ, Hunter TB, Hillman BJ. Radiology reporting: attitudes of referring physicians. *Radiology* 1988;169:825–6.
122. NHS Breast Screening Programme. *Information and advice for radiographer*. 19. Sheffield: NHS Breast Screening Programme, 1997.
123. Marteau TM. Framing of information: its influence upon decisions of doctors and patients. *Br J Soc Psychol* 1989;28 (Pt 1):89–94.
124. McNeil BJ, Pauker SG, Sox HC, Jr., Tversky A. On the elicitation of preferences for alternative therapies. *N Engl J Med* 1982;306:1259–62.
125. Sheldon JM, Fetting JH, Siminoff LA. Offering the option of randomized clinical trials to cancer patients who overestimate their prognoses with standard therapies. *Cancer Invest* 1993;11:57–62.

126. Patterson C, Teale C. Influence of written information on patients' knowledge of their diagnosis. *Age Ageing* 1997;26:41–2.
127. Richards C. *Radio National, the Law Report. Health law under the microscope.* [www.abc.net.au/rn/talks/8.30/lawrpt/stories/s220552.htm](http://www.abc.net.au/rn/talks/8.30/lawrpt/stories/s220552.htm) (last updated 6 December 2000).
128. Langlands AO. Breast cancer and malpractice litigation. *Med J Aust* 1998;169:212–4.
129. The Royal Australian and New Zealand College of Radiologists. *List of radiology facilities accredited with RANZCR.* [www.racr.edu.au/open/breast\\_mamm.htm](http://www.racr.edu.au/open/breast_mamm.htm) The Royal Australian and New Zealand College of Radiologists, (last updated 2000).
130. Young K. Can quality assurance of mammographic systems improve the detection of breast cancer? In International Breast Ultrasound School and Albert-Ludwigs-Universität Friburg. *The 2nd International breast imaging update IBIU '99*, Baden, Switzerland: International Breast Ultrasound School, 1999: 153–161.
131. MacFalda PA. Performance improvement: how to get employee buy-in. *Radiol Manage* 1998;20:35–44.
132. Modder U, Strasser G, Strasser E, Rex B. [The quality offensive in radiology]. *Radiologe* 1998;38:236–40.
133. Crabbe JP, Frank CL, Nye WW. Improving report turnaround time: an integrated method using data from a radiology information system. *AJR Am J Roentgenol* 1994;163:1503–7.
134. Gibson TP. Continuous quality improvement at work in radiology. *Radiol Manage* 1992;14:48–51.
135. Mattern CW, King BF, Jr., Hangiandreou NJ, Swenson A et al. Electronic imaging impact on image and report turnaround times. *J Digit Imaging* 1999;12:155–9.

136. Seltzer SE, Kelly P, Adams DF, Chiango BF et al. Expediting the turnaround of radiology reports: use of total quality management to facilitate radiologists' report signing. *AJR Am J Roentgenol* 1994;162:775–81.
137. Seltzer SE, Kelly P, Adams DF, Chiango BF et al. Expediting the turnaround of radiology reports in a teaching hospital setting. *AJR Am J Roentgenol* 1997;168:889–93.
138. Treutenaere JM. [Radiological reports and computer-assisted diagnosis]. *Ann Radiol (Paris)* 1993;36:360–4.
139. Wheeler PS, Raymond S. The computer-based cumulative report: improvement in quality and efficiency. *Radiology* 1992; 182:355–7.
140. Elmore JG, Wells CK, Howard DH. Does diagnostic accuracy in mammography depend on radiologists' experience? *J Womens Health* 1998;7:443–9.
141. Sobel JL, Pearson ML, Gross K, Desmond KA, et al. Information content and clarity of radiologists' reports for chest radiography [see comments]. *Acad Radiol* 1996;3:709–17.
142. Haug PJ, Farrell M, Frear J, Blatter D, Frederick PR. Developing a radiology data base for quality assurance. *J Digit Imaging* 1997;10:103–8.
143. Dacher JN, Lechevallier J. [The exam request seen by the radiologist, the report seen by the clinician]. *J Radiol* 1999;80:855–8.
144. Ley P, Whitworth MA, Skilbeck CE, Woodward R et al. Improving doctor-patient communication in general practice. *J R Coll Gen Pract* 1976;26:720–4.
145. Devine EC, Westlake SK. The effects of psychoeducational care provided to adults with cancer: meta-analysis of 116 studies. *Oncol Nurs Forum* 1995;22:1369–81.



146. Mumford E, Schlesinger HJ, Glass GV. The effect of psychological intervention on recovery from surgery and heart attacks: an analysis of the literature. *Am J Public Health* 1982;72:141–51.
147. The Royal Australian and New Zealand College of Radiologists. *Continuing professional development. Information manual for diagnostic radiology*. Sydney: The Royal Australian and New Zealand College of Radiologists, 2001.
148. American College of Radiology. *ACR accreditation programs*. [www.acr.org/departments/stand\\_accred/accreditation](http://www.acr.org/departments/stand_accred/accreditation) American College of Radiology (last updated 2000).
149. American Institute of Ultrasound in Medicine. *AIUM Ultrasound Practice Accreditation*. <http://www.aium.org/accreditation/practice/one.asp> (last updated 2000).
150. Brown G. *Guide to AIR professional development 2000 to 2002*. Victoria: Australian Institute of Radiography, 2000.
151. McEnery KW, Roth SM, Walkup RV. Radiology CME on the Web using secure document transfer and internationally distributed image servers. *Proc AMIA Annu Fall Symp* 1996;37–40.
152. McEnery KW, Roth SM, Kelley LK, Hirsch KR et al. A method for interactive medical instruction utilizing the World Wide Web. *Proc Annu Symp Comput Appl Med Care* 1995;502–7.
153. Newman L. *Developing technologies for early detection of breast cancer. A public workshop summary*. Washington, DC: National Academy Press, 2000.
154. Sunshine JH, McNeil BJ. Rapid method for rigorous assessment of radiologic imaging technologies. *Radiology* 1997;202:549–57.

155. McMahon K, Osborne D, Davidson A. Role of breast magnetic resonance imaging in difficult diagnostic situations. *Med J Aust* 2001;175:494–7.
156. Newman L. *Developing technologies for early detection of breast cancer: Summary of a public workshop #2*. Washington.D.C.: National Academy Press, 2000.
157. Drew PJ, Turnbull LW, Chatterjee S, Read J et al. Prospective comparison of standard triple assessment and dynamic magnetic resonance imaging of the breast for the evaluation of symptomatic breast lesions. *Ann Surg* 1999;230:680–5.
158. Kinkel K, Helbich TH, Esserman LJ, Barclay J et al. Dynamic high-spatial-resolution MR imaging of suspicious breast lesions: diagnostic criteria and interobserver variability. *AJR Am J Roentgenol* 2000;175:35–43.
159. The UK MRI Breast Screening Study Advisory Group, Brown J, Coulthard A, Dixon A et al. Rationale for a national multi-centre study of magnetic resonance imaging screening in woman at genetic risk of breast cancer. *The Breast* 2000;9:72–7.
160. Kaiser W. MR Mammography. In International Breast Ultrasound School and Albert-Ludwigs-Universitat Freiburg. *The 2nd International breast imaging update IBIU '99*, Baden, Switzerland: International Breast Ultrasound School, 1999: 22–23.
161. Van Ongeval C. MR imaging of the breast – present indications. *JBR-BTR* 2000;83:80–4.
162. Orel SG. MR imaging of the breast. *Radiol Clin North Am* 2000;38:899–913.
163. Robert G, Milne R. Positron emission tomography: establishing priorities for health technology assessment. *Health Technol Assess* 1999;3:1–54.

164. Moser E, Schumacher T, Reinhardt M, Nitzsche E. Scintigraphy and PET. In International Breast Ultrasound School and Albert-Ludwigs-Universität Freiburg. *The 2nd International breast imaging update IBIU 99*, Baden, Switzerland: International Breast Ultrasound School, 1999: 25–26.
165. Kakuda JT, Stuntz ME, Vargas HI, Khalkhali I. Status of scintimammography and its relationship to other detection methods for breast cancer. *Cancer Biother Radiopharm* 1999;14:435–42.
166. Sillar R, Howarth D, Clark D. The initial Australian experience of technetium-99M sestamibi scintimammography: a complementary test in the management of breast cancer. *Aust N Z J Surg* 1997;67:433–7.
167. Leitha T. Scintimammography. In International Breast Ultrasound School and Albert-Ludwigs-Universität Freiburg. *The 2nd International breast imaging update IBIU '99*, Baden, Switzerland: International Breast Ultrasound School, 1999: 143–145.
168. Martin JE. Breast imaging techniques. Mammography, ultrasonography, computed tomography, thermography, and transillumination. *Radiol Clin North Am* 1983;21:149–53.
169. BreastScreen Australia. *Statement on use of thermography to detect breast cancer*. Canberra: BreastScreen Australia, 1997.